EMERGING BIOLOGICAL SOLUTIONS FOR SPORTS INJURIES

Dr. Patrick Goh
Specialist Sports Physician
Sports Medicine International

Singapore Sports Institute, 3rd Annual Symposium, 11th Nov 2014

Biologics

- Medicinal product manufactured in or extracted from biological sources
- Includes
  - Whole blood or blood components
  - Stem Cells
  - Organs / Tissues
  - Antibodies
  - Etc

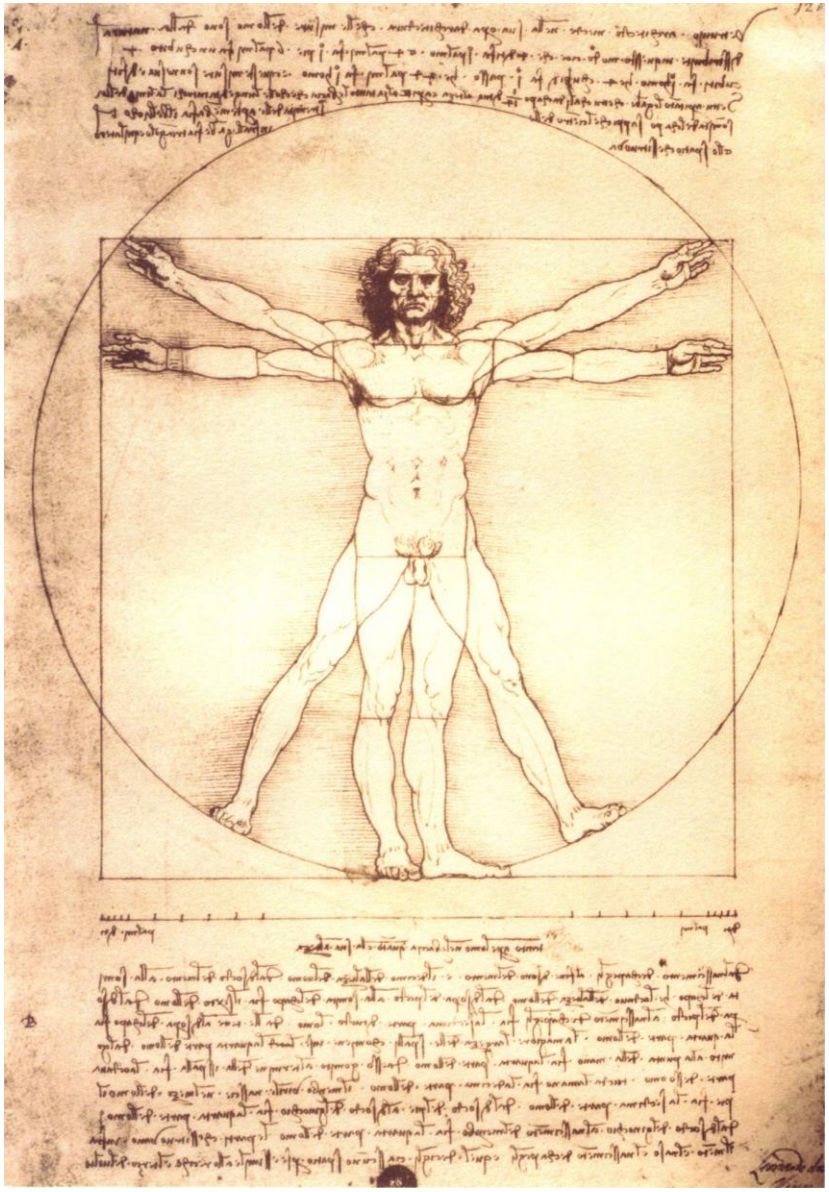

The ideal sports injury treatment…

- Little or no down time
- No risk
- Works fast without long term issues
- Solves the problem without creating another
- No surgery
- Legal / No Doping

“Over the past decade, we have come to expect a lot more of platelets. In addition to their established role in hemostasis and thrombosis, they have been credited with roles in inflammation, atherosclerosis, angiogenesis, wound healing, antimicrobial host defense, and malignancy”

Robert Flaumenhaft, MD, PhD, The Hematologist, 2011

PLATELET RICH PLASMA


Aurasma

Platelets

- produced in bone marrow, by budding off from megakaryocytes.
- lifespan of platelets is 7-10 days.
- In the steady state, where platelet production = platelet destruction, daily production is 30,000 - 40,000 /uL

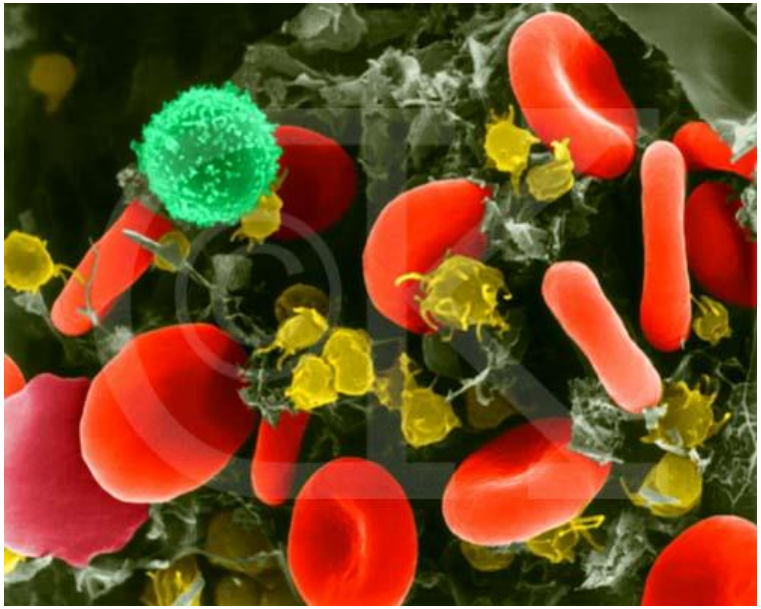

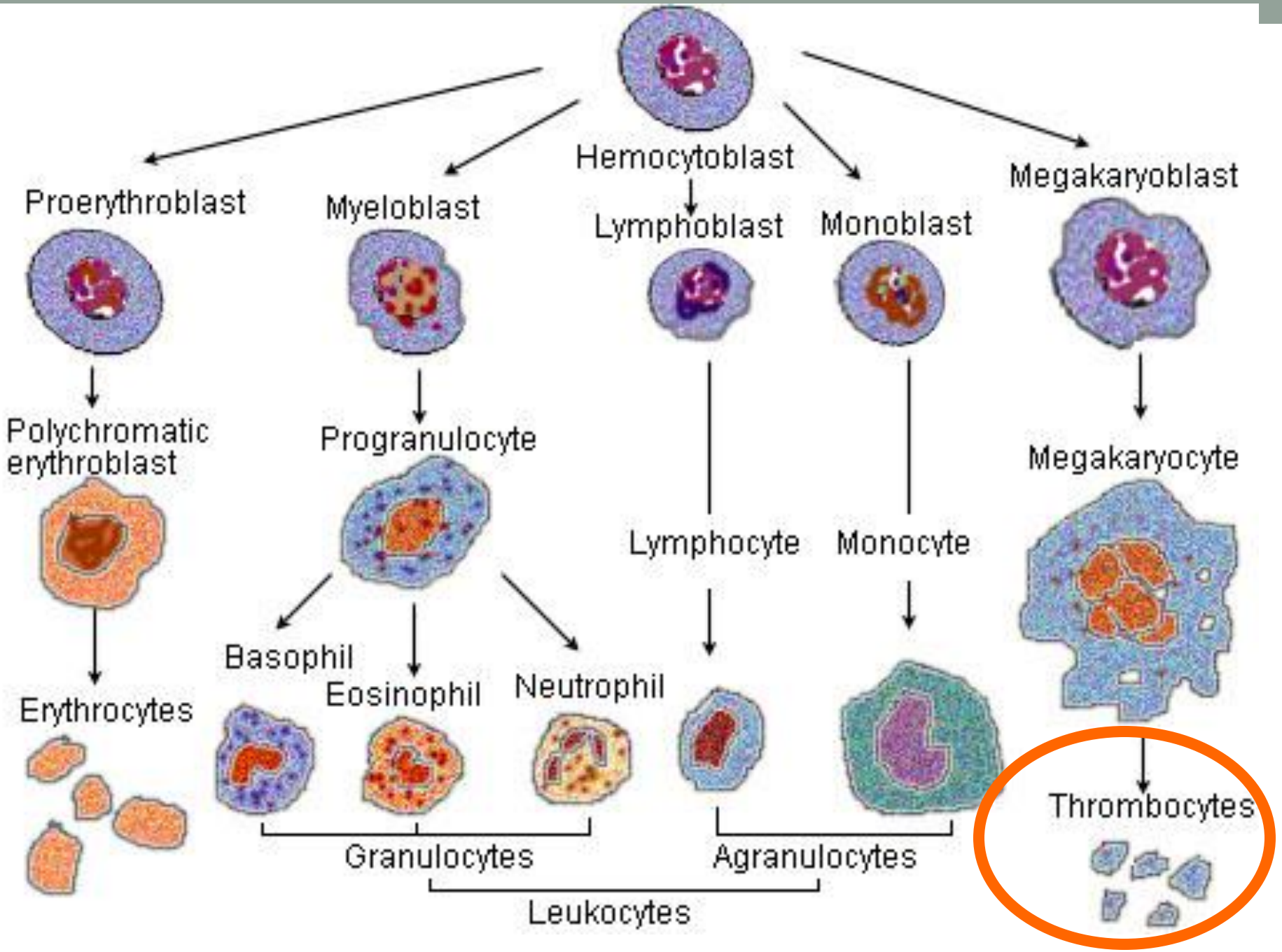
Hemocytoblast
Proerythroblast
Myeloblast
Lymphoblast
Monoblast
Megakaryoblast
Polychromatic erythroblast
Progranulocyte
Lymphocyte
Monocyte
Megakaryocyte
Basophil
Eosinophil
Neutrophil
Erythrocytes
Thrombocytes
Granulocytes
Agranulocytes
Leukocytes

- Platelets are in resting state while in circulation (intact vessel endothelium)
- If platelet encounters a break in the endothelium, it encounters molecules that trigger its activation. Eg. **collagen**, (found almost everywhere except within blood vessel)

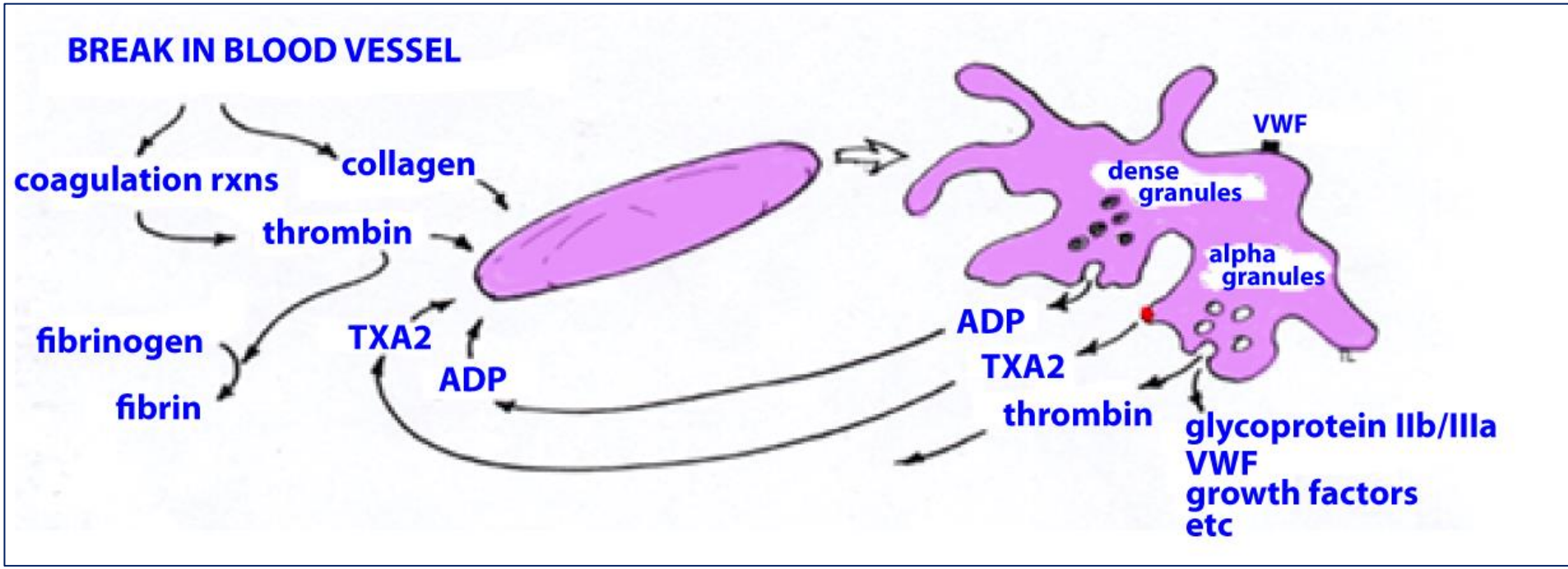

Platelet Activity

- Platelets begin to actively secrete growth factors within 10 minutes of clotting, and more than 95% of the pre-synthesised GF's are secreted within one hour.

- After initial burst of GF Release, platelets synthesize and secrete additional GF's for the remainder of their life span (max 8 days)

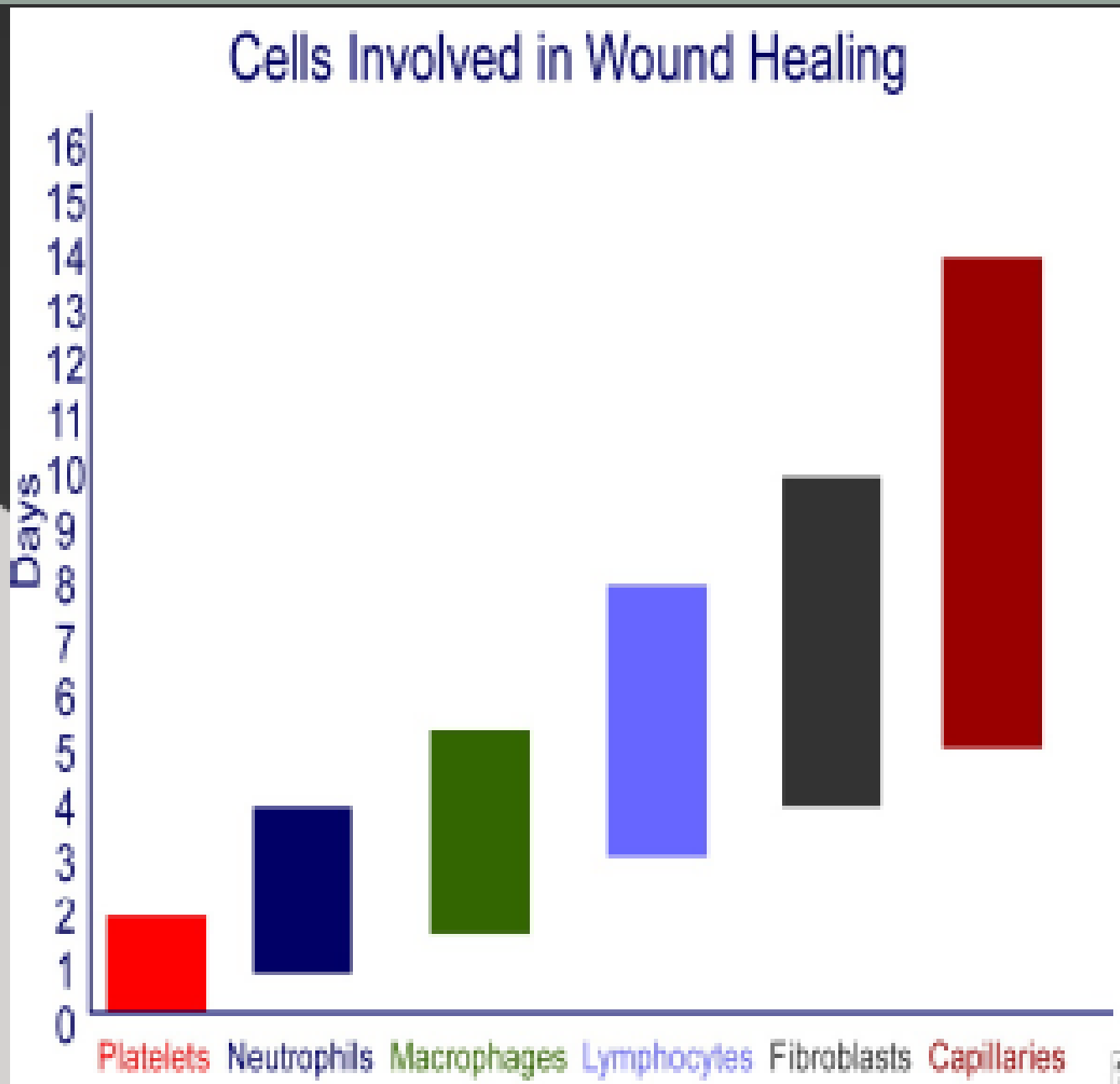
Cells Involved in Wound Healing
Days
0
1
2
3
4
5
6
7
8
9
10
11
12
13
14
15
16
Platelets
Neutrophils
Macrophages
Lymphocytes
Fibroblasts
Capillaries

α-Granules in Platelets

- More than other granule types (Dense Granules, Lysosomes)
- Contain hundreds of different protein cargos
- Some of these cargos have opposing activities, such as angiogenic (VEGF) and anti-angiogenic (Angiostatin)
- Suggests that platelet secretion is pivotal to establishing and controlling the microenvironment at a wound site
- Cargos selectively released – mechanism unknown

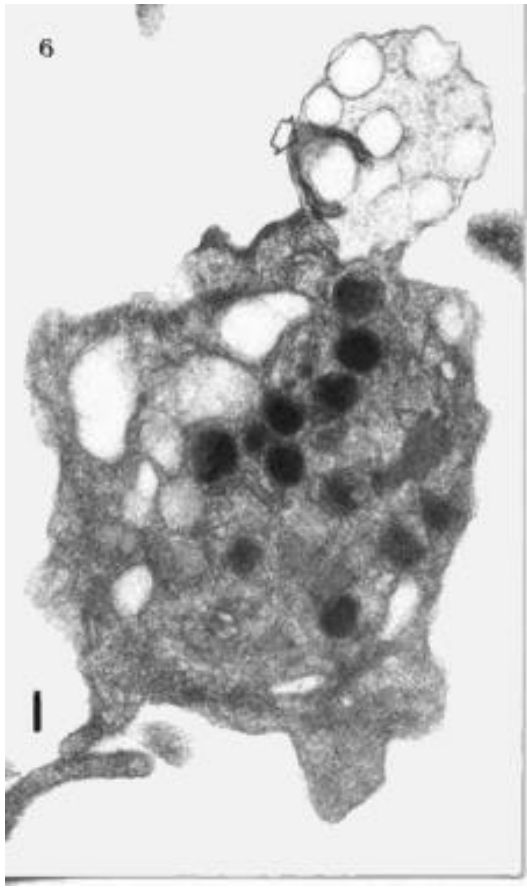

Growth factors in PRP

FACTOR	NAME	PRINCIPAL SOURCE	EFFECTS
PDGF aa PDGF bb PDGF ab	Platelet Derived GF	Activated Platlets	Mitogens of mesenchymal stem cells, Promote synthesis of extracellular matrix (Scaffold)
TGF–α TGF –β	Transforming GF	Activated Platlets	Stimulation of DNA Synthesis, Proliferation of various cells, Favours synthesis of collagen
IGF – I IGF – II	Insulin–like GF	Activated Platlets	Stimulates proliferation and differentiation of osteoblasts, Stimulate prolifiration of fibroblasts
EGF	Epidermal GF	Activated Platlets	Stimulates Proliferation and differentiation of epidermal cells, co–stimulating angiogenesis
VEGF	Vascular Endothelial GF	Leucocytes & Endothelial cells	Stimulate Angiogenesis and chemo–attraction of osteoblasts

Definition of Platelet Rich Plasma – No Consensus!

(Native Concentration of platelets is 140 – 440 X x 10^9 per litre)

- “Over 1,000 x 10^9 per litre”
- “High platelet concentration in a small volume of plasma”.
- “At least twice as high as in blood”.

Basic Science: PRP & tendons

- Increased tenocyte and collagen proliferation
- Promotes differentiation of tendon stem cells into active tenocytes
- improved collagen, glycosaminoglycan, and DNA content,
- **Stronger tendon**

De Mos M, van der Windt AE, Jahr H, et al. Can platelet-rich plasma enhance tendon repair? A cell culture study. Am J Sports Med. 2008;36(6):1171–8.

Wang X, Qiu Y, Triffitt J, et al. Proliferation and differentiation of human tenocytes in response to platelet-rich plasma: an in vitro and in vivo study. J Orthop Res. 2012;30(6):982–90.

Bosch G, van Schie HTM, de Groot MW, et al. Effects of platelet-rich plasma on the quality of repair of mechanically induced core lesions in equine superficial digital flexor tendons: a placebo-controlled experimental study. J Orthop Res. 2010;28(2):211–7.

Zhang J, Wang JH-C. Platelet-rich plasma releasate promotes differentiation of tendon stem cells into active tenocytes. Am J Sports Med. 2010;38(12):2477–86.

Aspenberg P, Virchenko O. Platelet concentrate injection improves Achilles tendon repair in rats. Acta Orthop Scand. 2004;75(1):93–9.

Basic Science: PRP & Muscles

- In mice with induced muscle contusion: PRP increased myofiber diameter regeneration and increased satellite cell activation, compared to control.

Wright-Carpenter T, Opolon P, Appell HJ, et al. Treatment of muscle injuries by local administration of autologous conditioned serum: animal experiments using a muscle contusion model. Int J Sports Med. 2004;25(8):582–7.

Basic Science: PRP & Meniscus

- Regenerative effects on meniscal cells in vitro
- PRP combined with a hydrogel had beneficial healing effects on surgically induced meniscal lesions in a rabbit model

Ishida K, Kuroda R, Miwa M, et al. The regenerative effects of platelet-rich plasma on meniscal cells in vitro and its in vivo application with biodegradable gelatin hydrogel. Tissue Eng. 2007;13(5):1103–12.

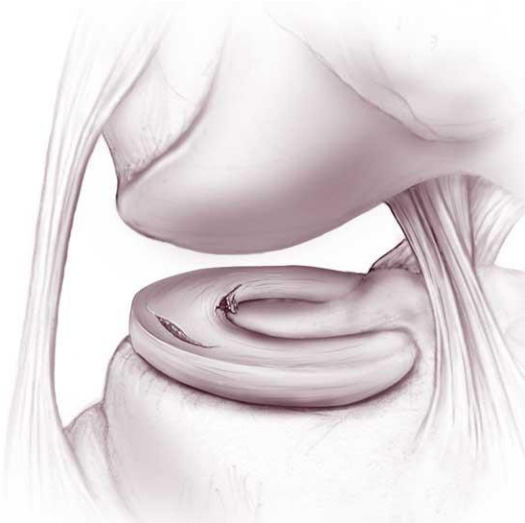

Basic Science: PRP & Cartilage

- Improved osteochondral healing relative to a control group in a rabbit model
- Decreased multiple inflammatory effects of IL-1 beta on human osteoarthritic chondrocytes (in vitro)
- PRP administration to chondrocytes resulted in a statistically significant increase in collagen synthesis and chondrocyte DNA relative to control.

- Sun Y, Feng Y, Zhang CQ, et al. The regenerative effect of platelet-rich plasma on healing in large osteochondral defects. Int Orthop. 2010;34(4):589–97.
- Van Buul GM, Koevoet WLM, Kops N, et al. Platelet-rich plasma releasate inhibits inflammatory processes in osteoarthritic chondrocytes. Am J Sports Med. 2011;39(11):2362–70.
- Akeda K, An HS, Okuma M, et al. Platelet-rich plasma stimulates porcine articular chondrocyte proliferation and matrix biosyn- thesis. Osteoarthr Cartil. 2006;14(12):1272–80.

Use in Sports Injuries

- Tendon –
  - Tennis Elbow, Achillis Tendinosis, Plantar Fasciitis, Patellar Tendon, Rotator Cuff
- Muscle
  - Calf Tear, Hamstring Tear
- Ligament
  - Knee MCL, Ankle ATFL
- Joint
  - Cartilage regeneration??
- Bone

Review Article

Platelet-rich Plasma in Orthopaedic Applications: Evidence-based Recommendations for Treatment

Wellington K. Hsu, MD
Allan Mishra, MD
Scott R. Rodeo, MD
Freddie Fu, MD
Michael A. Terry, MD
Pietro Randelli, MD
S. Terry Canale, MD
Frank B. Kelly, MD

J Am Acad Orthop Surg 2013;21:739-748

- Theoretical Benefit in augmenting tissue healing
- Success varies depending on preparation method, medical condition, anatomic location and tissue type

PRP Meta-Analysis

Sheth et al. J Bone Joint Surg Am. 2012;94:298-307

Meta-analysis of 33 ortho-studies (23 controlled, randomized; 10 prospective cohort)

- 9 studies found PRP improved functional outcomes
- 21 studies found no difference between PRP and Control
- 2 studies showed control worked better

Studies on Tennis Elbow

- Mirsha (2006)
  - 81% improvement in pain scores 6 months after PRP treatment.
- *Sluimer & Gosens (2007)*
  - *PRP vs. Cortisone*
  - *Significant relief in both but cortisone group relapsed by 6 months*

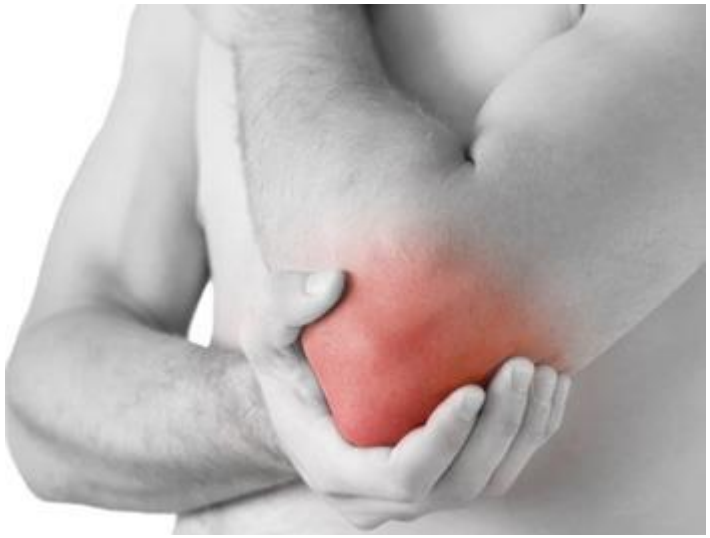

The American Orthopaedic Society for Sports Medicine
The American Journal of Sports Medicine

Impact Factor: 4.699 | **Ranking:** Orthopedics 1 out of 67 | Sport Sciences 4 out of 81 | **5-Year Impact Factor:** 5.009 | **5-Year Ranking:** Orthopedics 1 out of 67 | Sport Sciences 5 out of 81

Platelet-Rich Plasma Significantly Improves Clinical Outcomes in Patients With Chronic Tennis Elbow

A Double-Blind, Prospective, Multicenter, Controlled Trial of 230 Patients

Allan K. Mishra, MD[*,†], Nebojsa V. Skrepnik, MD, PhD[‡], Scott G. Edwards, MD[§], Grant L. Jones, MD[‖], Steven Sampson, DO[¶], Doug A. Vermillion, MD[#], Matthew L. Ramsey, MD[**], David C. Karli, MD, MBA[††] and Arthur C. Rettig, MD[‡‡]

+ Author Affiliations

ONLINEFIRST VERSION OF RECORD

This Article

Published online before print July 3, 2013, doi: 10.1177/0363546513494359

Am J Sports Med **July 3, 2013**
0363546513494359

» Abstract *Free*
Full Text
Full Text (PDF)

All Versions of this Article:
0363546513494359v1
0363546513494359v2
42/2/463 *most recent*

Journal of Ultrasound (2012) 15, 260–266

Available online at www.sciencedirect.com

SciVerse ScienceDirect

journal homepage: www.elsevier.com/locate/jus

Ultrasound-guided injection of platelet-rich plasma in chronic Achilles and patellar tendinopathy☆

G. Ferrero [a], E. Fabbro [a], D. Orlandi [a], C. Martini [a], F. Lacelli [b], G. Serafini [b], E. Silvestri [c], L.M. Sconfienza [d,e,*]

"PRP injection in patellar and Achilles tendinopathy results in a significant and lasting improvement of clinical symptoms and leads to recovery of the tendon matrix potentially helping to prevent degenerative lesions"

RCT on PRP and Achilles Tendinosis

- One-Year Follow-up of Platelet-Rich Plasma Treatment in Chronic Achilles Tendinopathy: A Double-Blind Randomized Placebo-Controlled Trial
  De Vos et al, Am J Sports Med August 2011 vol. 39 no. 8 1623-1629
  - Result: PRP no different from placebo at 6 months
  - However:
    - Combined PRP/Control with Eccentric Programme
    - No Activation of platelets
    - Only 1 PRP shot, followed by 6 month outcome
    - Limited external validity

Whole Blood injections Tendons

- Effective on Pateller Tendinopathy (Combined with Physiotherapy)

  (James, Ali, Pocock, BJSM, 2007)
- 2 recent RCT's on Whole Blood vs. PRP for Tennis Elbow showed PRP more effective
  - (Raeissadat et al, 2014, Thanasas et al, 2011)
- 1 recent RCT showed Whole Blood more effective (Creaney, 2011)

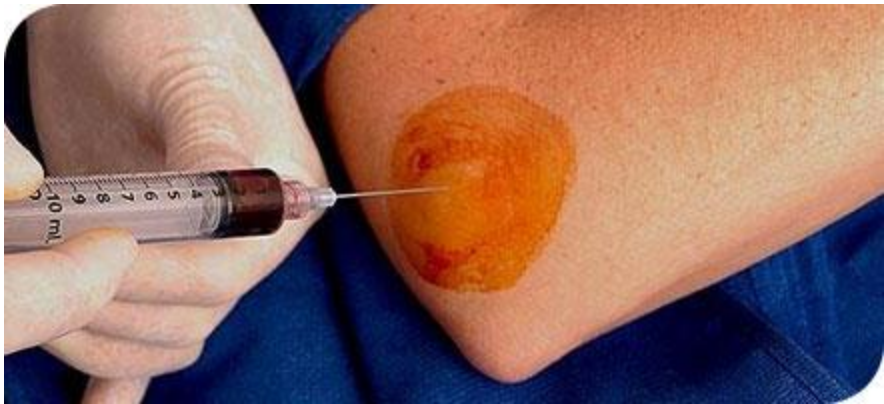

PRP results for tendons

- Retrospective surveys of PRP tendon results based on patient records 2011 – 2013.
- Pain reduction following PRP (n=101)
- Post-PRP injection soreness
- Various sports - mainly running, soccer, racket sports
- All injections Ultrasound Guided

P Goh. Biobridge 2013

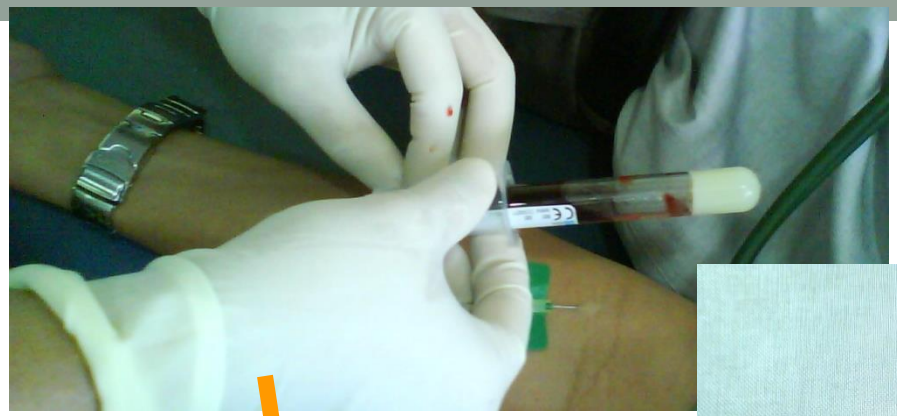



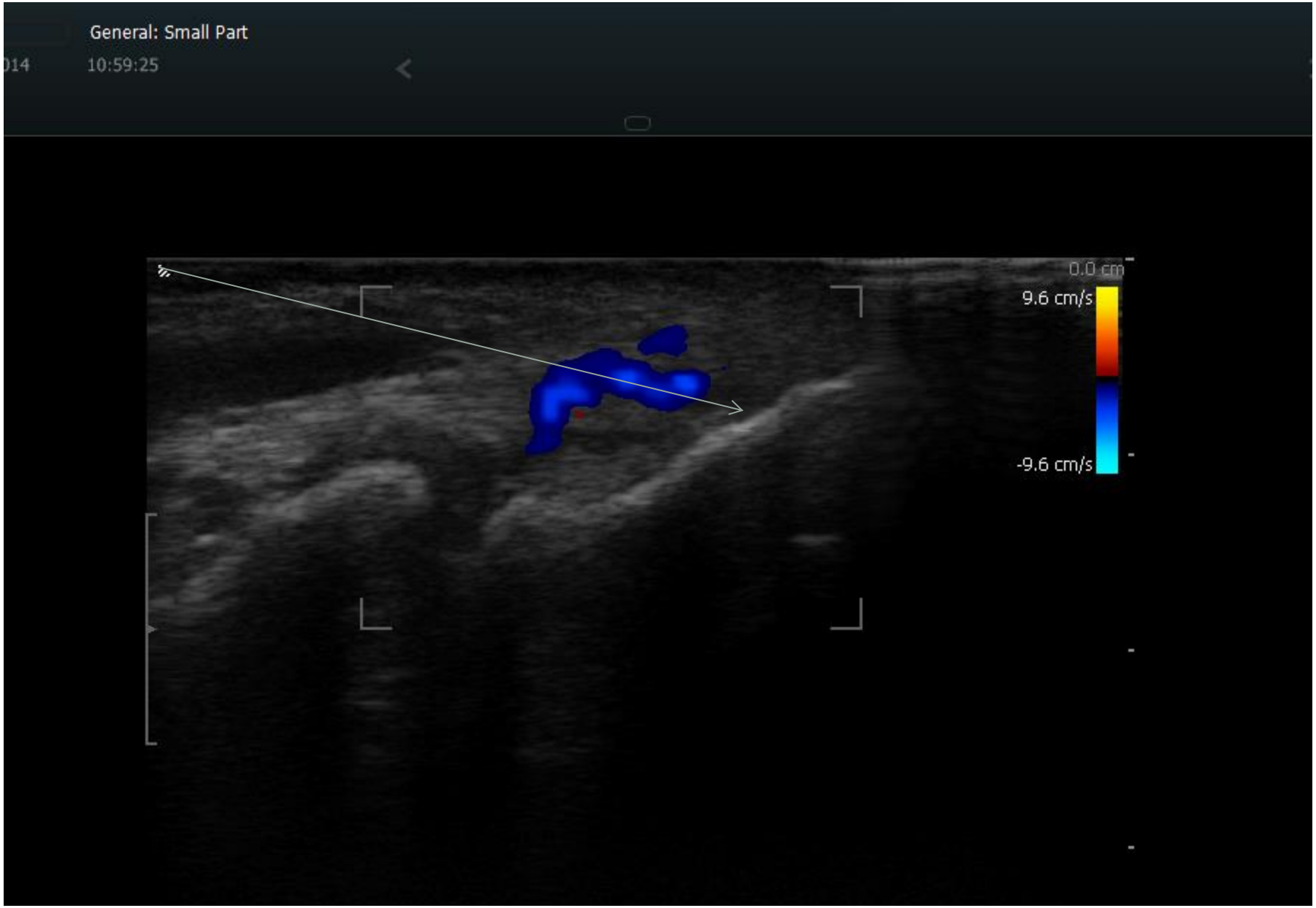
General: Small Part
014
10:59:25
0.0 cm
9.6 cm/s
-9.6 cm/s

Distribution by sport

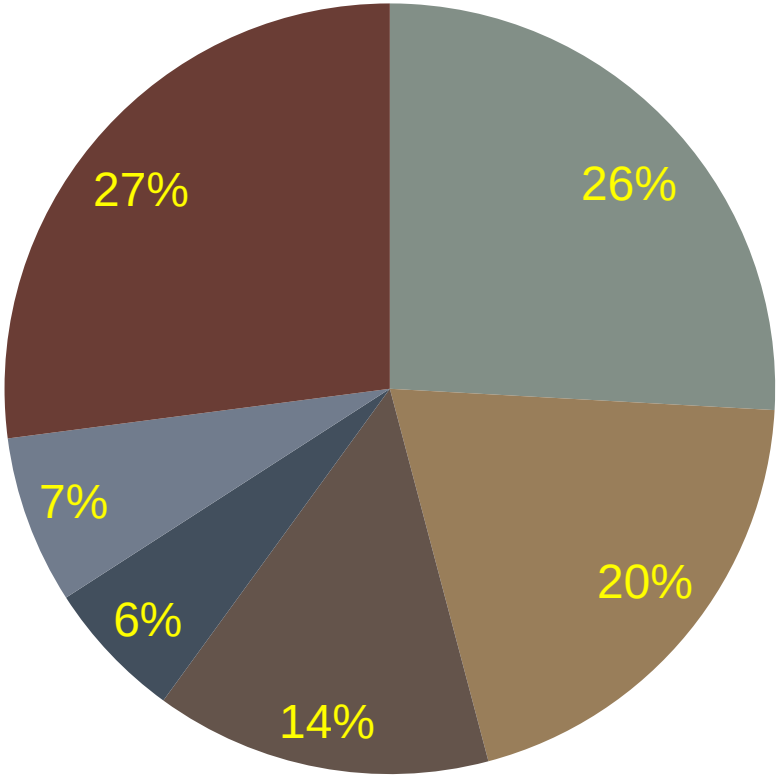

- Running
- Racket sport
- Soccer
- Waterski/wakeboard
- Weights/Gym
- Others*

Martial Arts, Golf, Rowing, Basketball, Rowing, Swimming, Diving,

P Gph. Biobridge 2013

DISTRIBUTION OF TENDON INJURY SITES

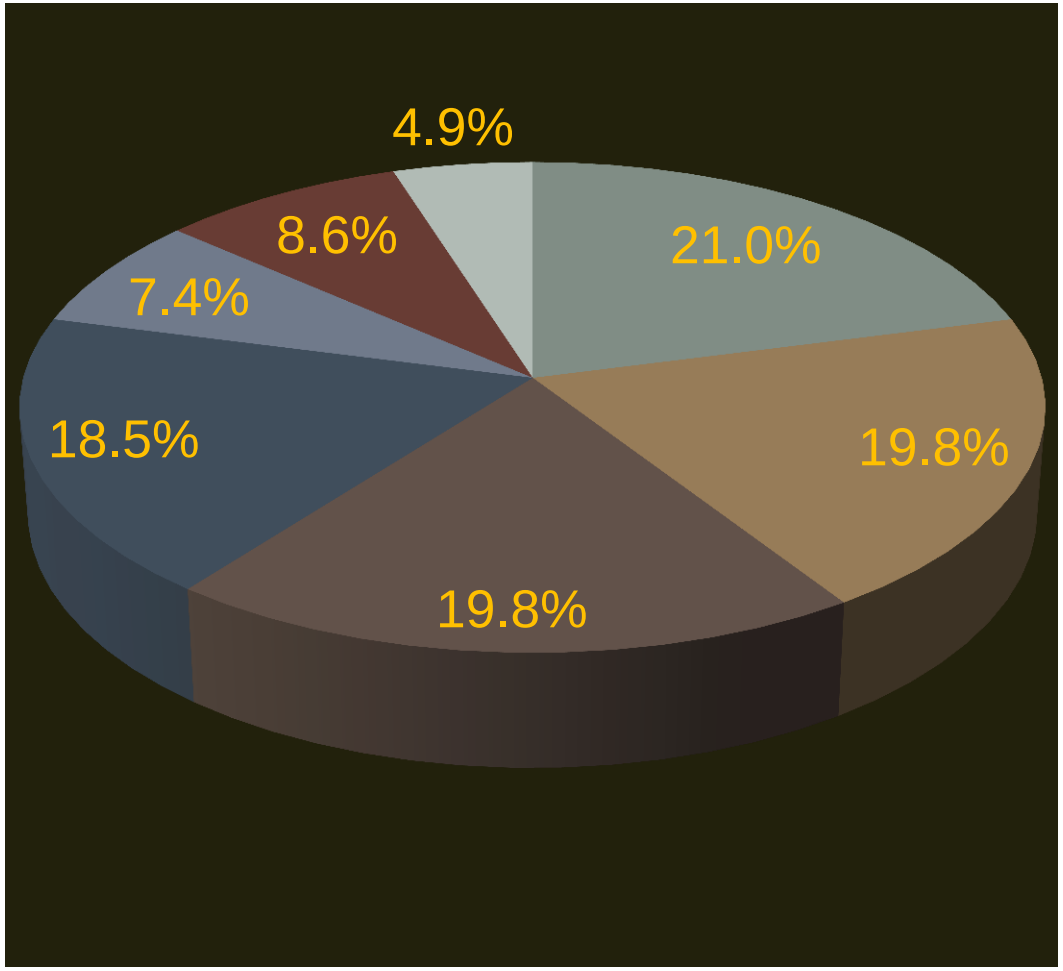

N=101

Tendon: Pain Reduction post-PRP

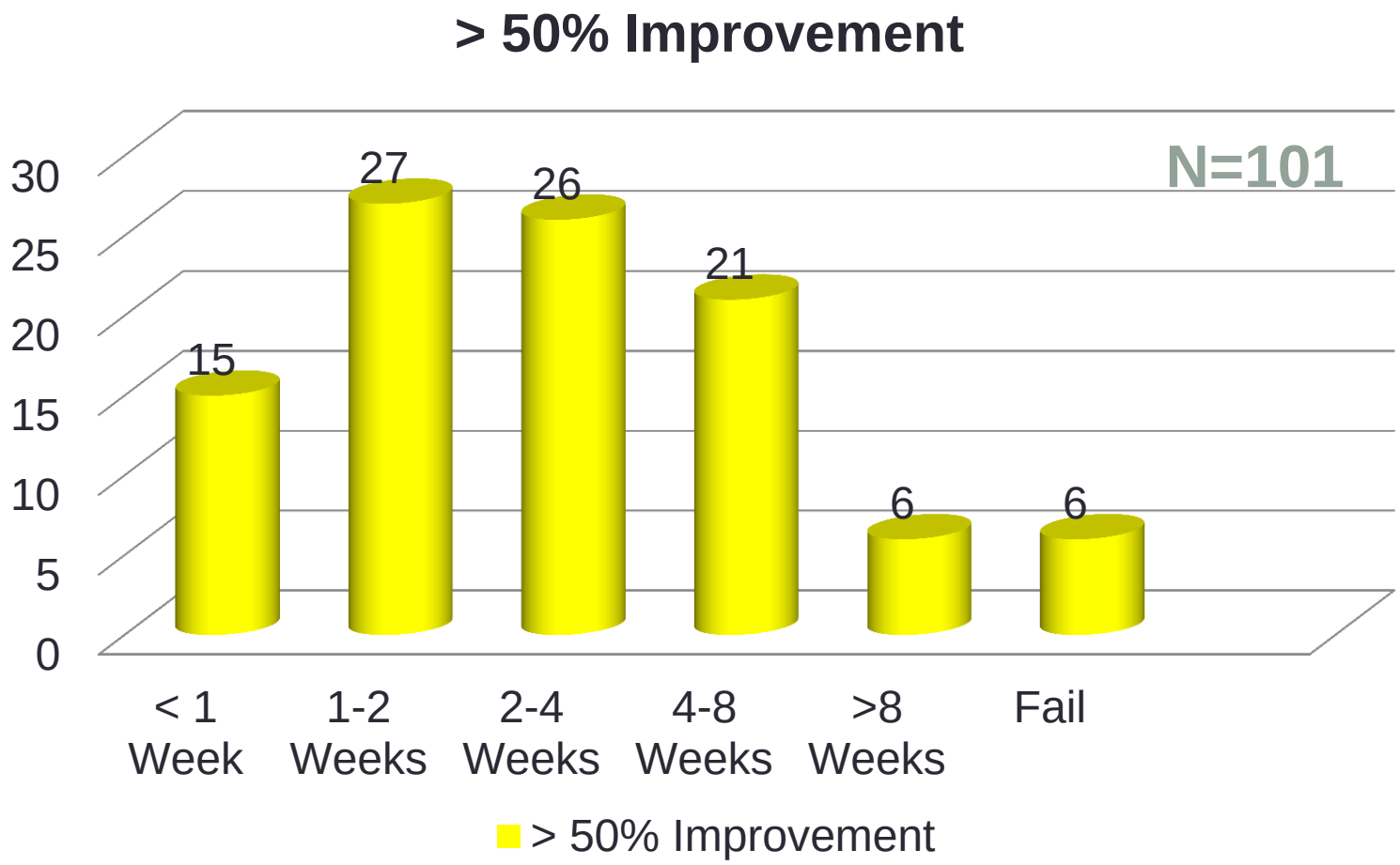

. Gph P, 2013,Unpublished

Tendon Soreness Following PRP injection (2013)

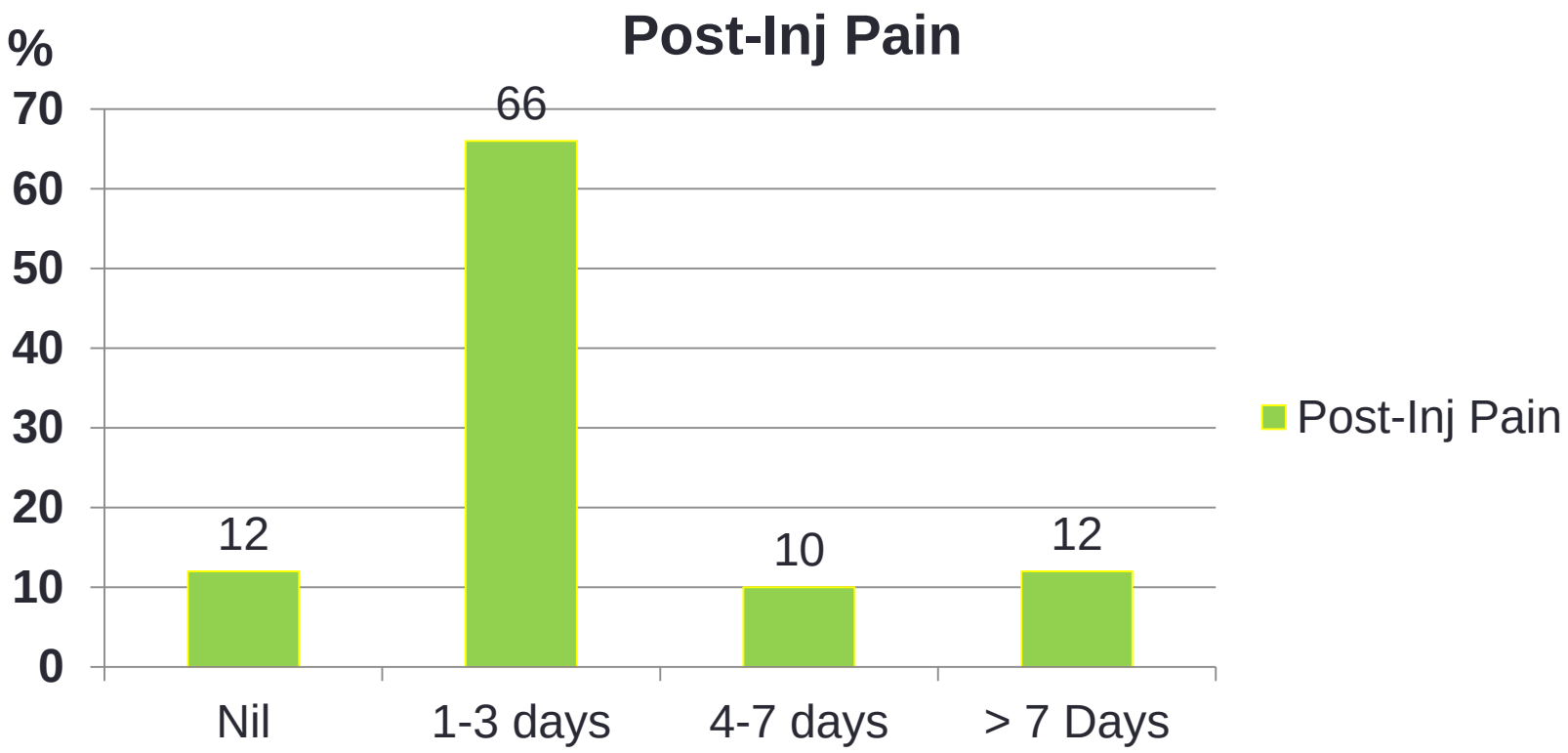

Goh, P / Sports Medicine Int'l. 2013. Unpublish

PRP Treatment for tendons

Summary of Clinical Response

- **67% Achieved Pain Reduction > 50% within 4 weeks,**
- **88% within 8 weeks**
- **78% experience of soreness for 0-3 days**
- **88% experience soreness for < 1 week**

P Gph. Biobridge 2013

Muscle Injections

- 2x Faster Healing (Sanchez)
  - What does this mean in real terms?
- Most tears:
  - Myo-tendinous / Myo-septal
  - Seen on Ultrasound
  - Hematoma
  - Proximal Spasm

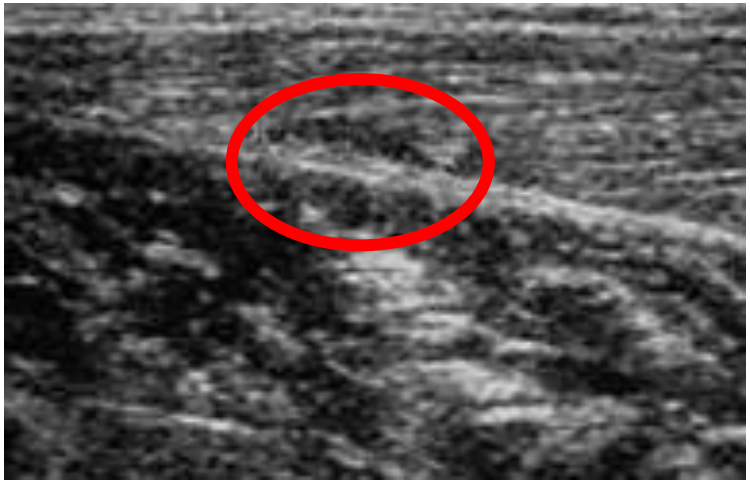

The American Orthopaedic Society for Sports Medicine
The American Journal of Sports Medicine

HOME | ALL ISSUES | FEEDBACK | SUBSCRIBE | RSS | EMAIL ALERTS | HELP

Sign In to gain access to subscriptions and/or My Tools.

Impact Factor: 4.699 | **Ranking:** Orthopedics 1 out of 67 | Sport Sciences 4 out of 81 | **5-Year Impact Factor:** 5.009 | **5-Year Ranking:** Orthopedics 1 out of 67 | Sport Sciences 5 out of 81

Platelet-Rich Plasma Injections for the Treatment of Hamstring Injuries

A Randomized Controlled Trial

Mohamad Shariff A Hamid, MBBS, M Sports Med*,†, Mohamed Razif Mohamed Ali, MBBCh BAO, FRCS(Edin), MSc, M Sports Med‡, Ashril Yusof, BMS, MSES, PhD§, John George, MBBS, DMDS, FRCR|| and Leena Poh Chen Lee, MMedSc, BSc App Rehab¶

+ Author Affiliations

* Mohamad Shariff A Hamid, Sports Medicine Unit, Faculty of Medicine, University of Malaya, 50603 Kuala Lumpur, Malaysia (e-mail: ayip@um.edu.my).

« Previous | Next Article »
Table of Contents

This Article

Published online before print July 29, 2014, doi: 10.1177/0363546514541540

Am J Sports Med **October 2014** vol. 42 no. 10 **2410–2418**

» Abstract *Free*
Full Text
Full Text (PDF)
Supplementary Material

All Versions of this Article:
0363546514541540v1
42/10/2410 *most recent*

A single autologous PRP injection combined with a rehabilitation program was significantly more effective in treating hamstring injuries than a rehabilitation program alone

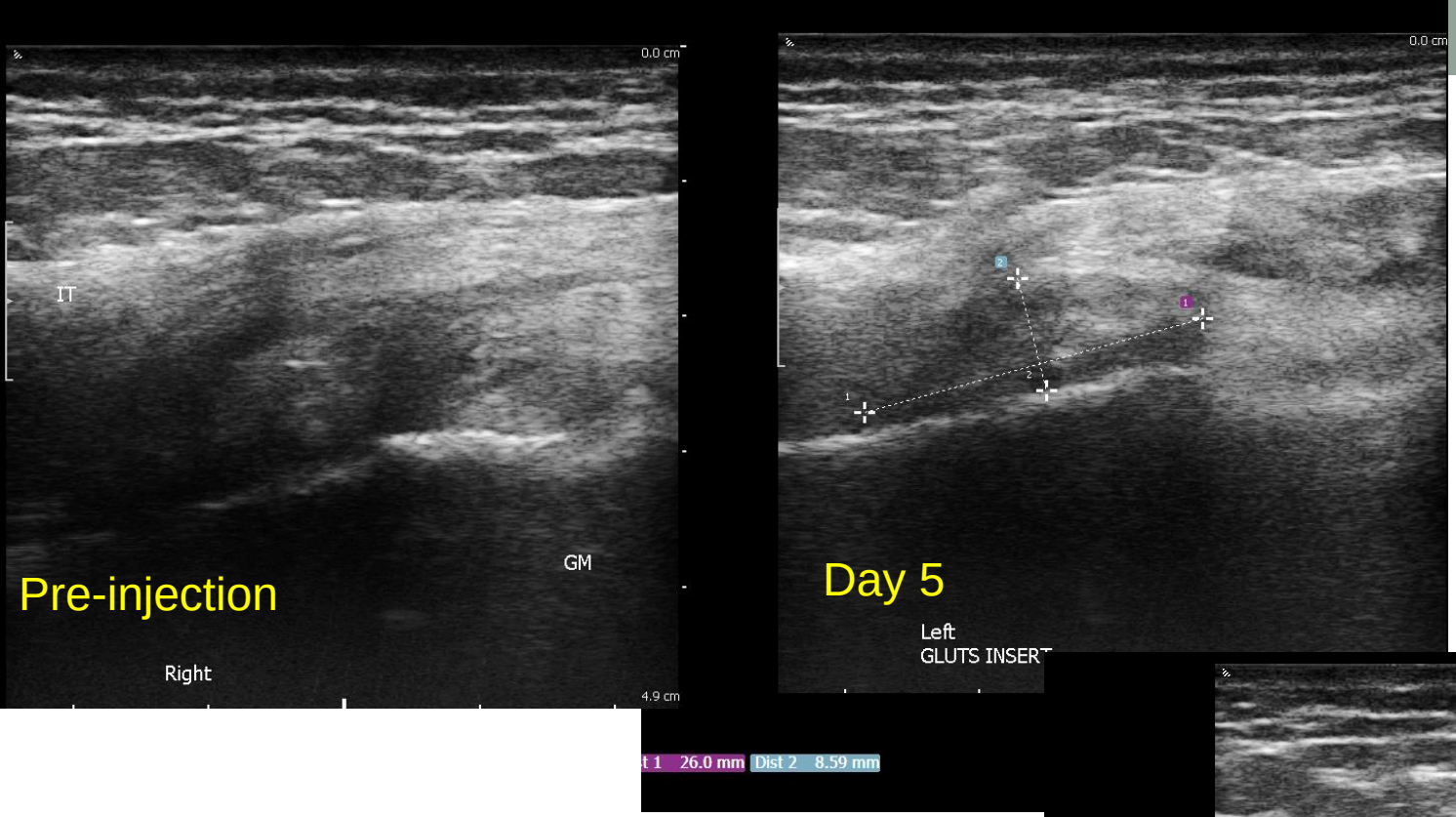

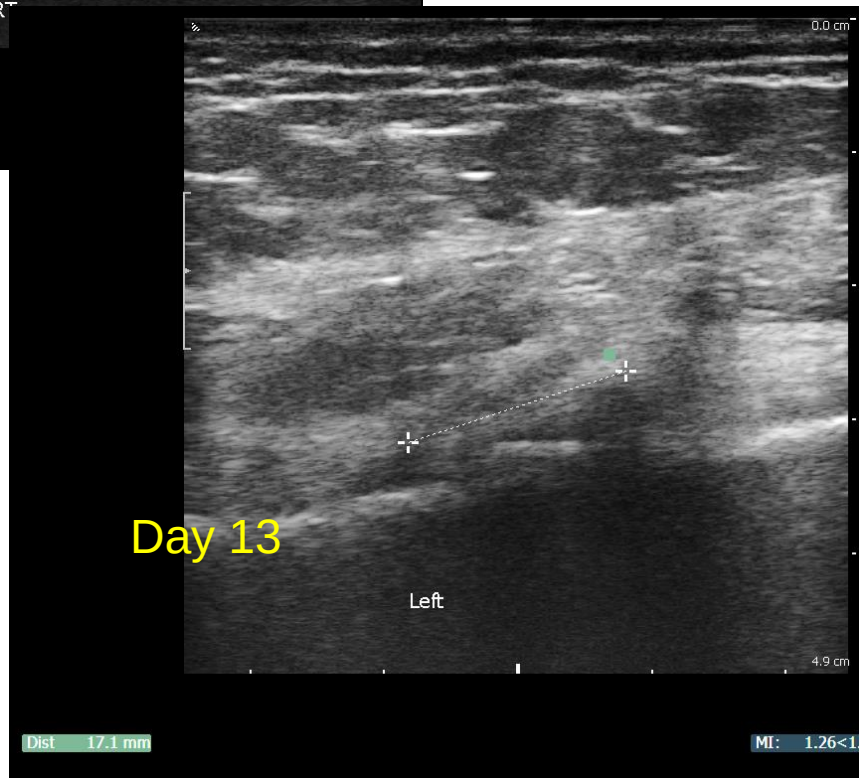

M/29 National Soccer Player
Tear of Gluteus Attachment to ITB
Acute on Chronic
3 days old

PRP and Cartilage

What we have seen is a transition from a traditional approach focusing on the concept of “repair” to the revolutionary idea of “regeneration”

PRP For the Treatment of Cartilage Pathology
Elizaveta Kon, Giuseppe Filardo, Berardo Di Matteo and Maurilio Marcacci
The Open Orthopaedics Journal, 2013, 7, (Suppl 1: M2) 120-128

PRP and Cartilage

Table 2. PRP Conservative Application in Cartilage Pathology

Authors, Journal and Year	Level of Evidence	Pathology	Protocol	Control Group	Patients	Follow-Up	Outcome
SANCHEZ *et al.* Clin Exp Rheumatol 2008	Retrospective comparative study	Knee condropathy or OA	3 weekly injections of PRP	Yes	30 PRP *vs* 30 HA	5 weeks	Better pain control and functional outcome in PRP group
SAMPSON *et al.* Am J Phys Med Rehabil 2010	Case series	Knee condropathy or OA	3 injections of PRP one month apart	No	14 PRP	6 months	Clinical improvement at short term evaluation
WANG-SAEGUSA *et al.* Arch orthop Trauma Surg 2011	Case series	Knee condropathy or OA	3 injections of PRP two weeks apart	No	261 PRP	6 months	Clinical improvement at short term evaluation
KON *et al.* Knee Surg Sport traumatol Arthrosc 2010 Knee Surg Sport Traumatol Arthrosc 2011	Case series	Knee condropathy or OA	3 injections of PRP two weeks apart	No	100 PRP	24 months	Significant pain reduction and functional recovery. Time dependent effect of PRP injections with a mean beneficial effect of 9 months
KON *et al.* Arthroscopy 2011	Comparative trial	Knee condropathy or OA	3 weekly injections of PRP	Yes	50 PRP *vs* 50 LWHA *vs* 50 HWHA	12 months	Best results for PRP in chondropathy group, no statistical difference between treatment for higher degree of cartilage degeneration

FILARDO *et al.* Knee Surg Sport Traumatol Arthrosc 2011	Comparative trial	Knee condropathy or OA	3 weekly injections of PRP	Yes	72 leukocyte rich PRP *vs* 72 leukocyte free PRP	12 months	Comparable clinical results with higher post-injective pain in leukocyte -rich PRP group
NAPOLITANO *et al.* Blood Transfus 2012	Case series	Knee condropathy or OA	3 injections of PRP	No	27 PRP	6 months	Statistical improvement in pain and function
GOBBI *et al.* Sports Health 2012	Case series	Knee condropathy or OA	2 monthly injections of PRP	No	50 PRP	12 months	Statistical improvement in pain and function
SPAKOVA *et al.* Am J Phys Med Rehabil 2012	Prospective trial	Knee condropathy or OA	3 injections of PRP	Yes	60 PRP *vs* 60 HA	6 months	Superior results in PRP group at short term evaluation
SANCHEZ *et al.* Arthroscopy 2012	Randomized trial	Knee condropathy or OA	3 weekly injections of PRP	Yes	79 PRP *vs* 74 HA	6 months	Higher percentage of responders in PRP group but no clear superiority of the biological approach
CERZA *et al.* Am J Sport Med 2012	Randomized trial	Knee condropathy or OA	4 weekly injections of APC	Yes	60 ACP *vs* 60 HA	6 months	Superior clinical outcome for PRP in all groups of treatment
FILARDO *et al.* BMC 2012	Randomized trial	Knee condropathy or OA	3 weekly injections of PRP	Yes	55 PRP *vs* 54 HA	12 months	Clinical improvement in both groups without inter-group significant difference. Better trend for PRP in low grade cartilage pathology

“Based on current evidence, PRP treatment should only be indicated for low-grade cartilage degeneration and in case of failure of more traditional conservative approaches”

Some Variables in PRP injection treatment

- **Platelet Concentration (relative/absolute)**
- **Leukocyte Content**
- **RBC Content**
- Use of activator
- Use of LA
- Number and frequency of injections
- Dose per injection
- Injection target / technique
- Post-procedure protocol

These undermine the generalizability of any RCT on PRP

Leucocytes and PRP

- Leucocyte Rich PRP resulted in a greater inflammatory response 5 days post-injection than LP-PRP or controls (Dragoo, AJSM, 2012)

- Concern with neutrophils which contain MMP's which break down tissue. (Tidball et al 1995, 2005, Pizza 2001, Schnieder, 2007)

- However, Leucocytes in PRP are usually mononuclear cells (Mono/lymphcytes). Stem cells reside with mononuclear cell population. (Kevy et al 2012)

Red Blood Cells & PRP

- Significant evidence that RBC's are chondrotoxic both in vitro and in vivo –
  - Hemophiliacs with recurrent hemarthrosis get OA – Single exposure of cartilage to RBC's are chondrotoxic – Hooiveld et al, 2003, Roosendaal et al, 1999, Madhok et al, 1988
  - Mechanism - ?inhibition of proteoglycan synthesis
- Effect on Tendons?
  - Bleeding normal at site of tendon injury –
  - Will healing occur better with low RBC PRP vs normal RBC PRP ?

Optimising PRP

- Are more platelets better?
  - Yes, up to a point.
- Is there an inhibitory effect with higher platelet counts?
  - Possibly
- What is the optimal concentration of platelets?
  - Not known

Mautner, 2013

Future Directions for PRP

- Optimisation of PRP for specific injuries
  - Preparation
  - Protocol
  - Technique
- Strengthening base of evidence

STEM CELLS

WHAT ARE STEM CELLS?

- **“Master” Cells** – Building blocks of organs, tissues, blood etc
- **Sources**
  - Embryo
  - Umbilical Cord
  - Amniotic Fluid
  - Bone Marrow
  - Adipose Tissue
  - Blood

Not all Stem Cells are Equal…

- **“Totipotent”**
  - Can give rise to all cells and tissues including the whole organism (Cloning)
  - 1st 4 days of Embryonic cell differentiation
- **“Pluripotent”**
  - After 4th day of embryo
  - Can give rise nearly any human tissue but not whole organism
- **Induced Pluripotent Stemcells**
  - Pioneered in 2006 by Prof . Shinya Yamanaka in Japan
  - 2012 Nobel Prize
  - Introduction of 4 specific transcription factors could convert adult cells into pluripotent stem cells.

- **“Multipotent”**
  - Give rise to multiple cell lineages, but not all
  - Limited range
- Adult Stem Cells are Multipotent
- **“Adult Mesenchymal Stem Cells (MSC’s)”**
  - Bone Marrow,
  - Adipose Tissue (Fat)
  - Blood
  - Synovial Tissue
  - Tendon
  - Muscle

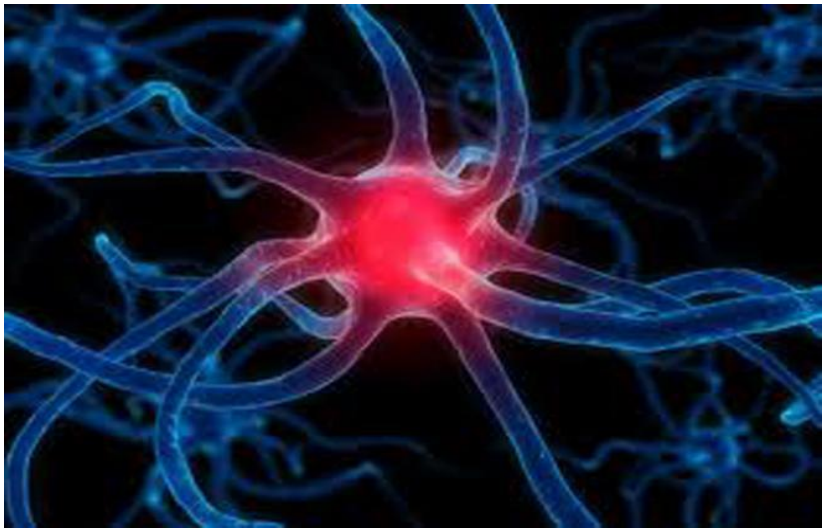

MSC Source
?
BONE MARROW vs FAT

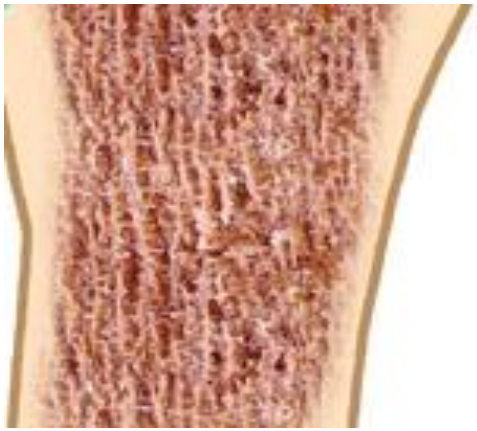

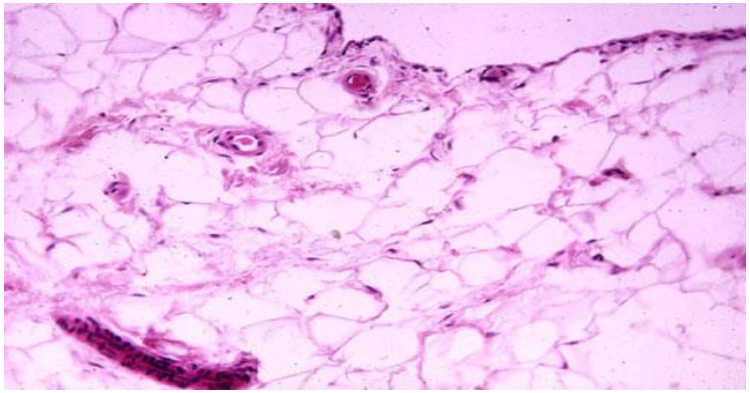

Bone Marrow – higher chondrogenic conversion

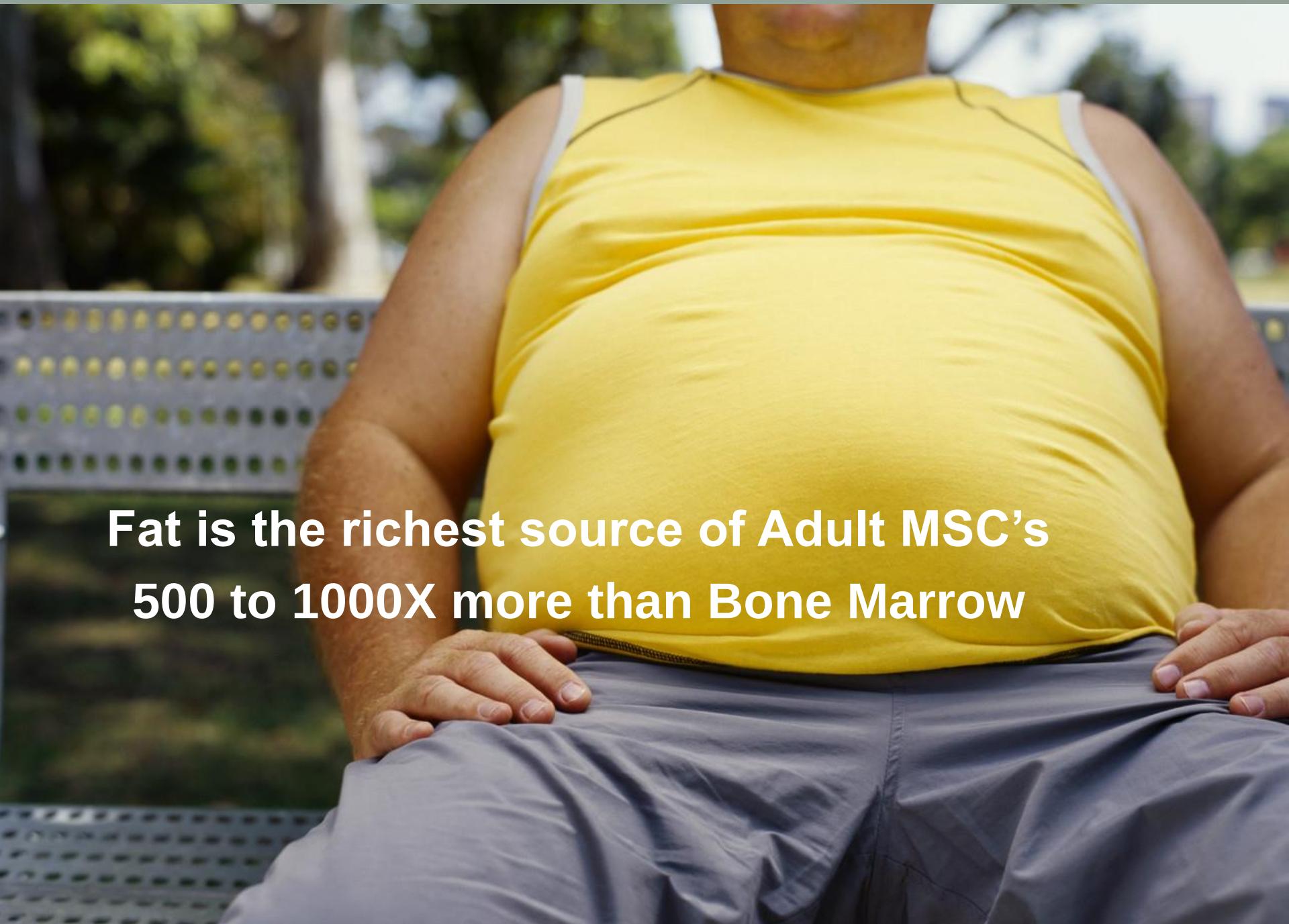
Fat is the richest source of Adult MSC's
500 to 1000X more than Bone Marrow

Fat Advantages

- Fat MSC's quality is affected less by doner age or morbidity compared to bone marrow MSC's. *(Murphy et al 2002, Zhu et al 2008, Izadpanah et al 2006, Chen et al 2012, Mirsaidi et al 2012)*
- Despite having relatively poorer potential to convert to chondrocytes (compared to marrow), studies showed Fat MSCs :
  - Reduced hypertrophy and de-differentiation of chondrocytes *(Maumus et al 2013),*
  - Inhibit synovial thickening, and protect against joint destruction (*Huurne et al 2012*)
  - Decreased the development and progression of osteoarthritis *(Toghraie et al 2011, Desando et al, 2013)*

How do stem cells work?

Differentiation Potential of Stem Cells

Cancer Treatment

- Haematopoietic stem cells (HSCs) used since 1959
- Transplantation used to repopulate blood after high dose chemotherapy and radiation
- HSCs differentiation potential is crucial to therapeutic outcome

Do MSC's work by differentiation?

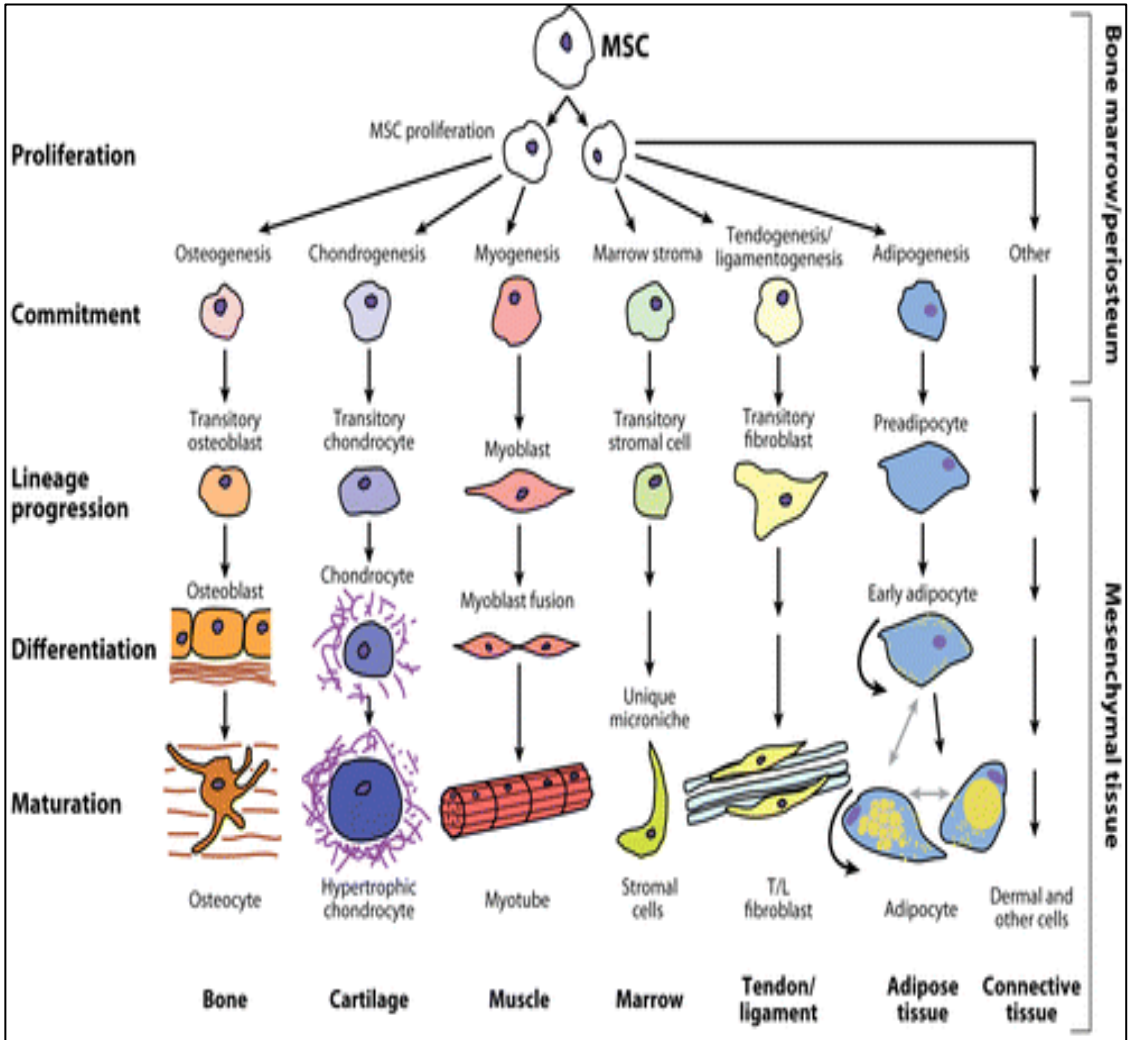

Singer NG, Caplan AI. 2011.
Annu. Rev. Pathol. Mech. Dis. 6:457–78

- Caplan (30 years stem cell research)
- Spent 20 years researching the ability of MSCs to differentiate into tissue types
- Not the current view

Trophic Mediation by MSC

Journal of Cellular Biochemistry 98:1076–1084 (2006)

Mesenchymal Stem Cells as Trophic Mediators

Arnold I. Caplan* and James E. Dennis

Department of Biology, Skeletal Research Center, Case Western Reserve University,
2080 Adelbert Road, MSC 118, Cleveland, Ohio 44106-7080

Abstract Adult marrow-derived Mesenchymal Stem Cells (MSCs) are capable of dividing and their progeny are further capable of differentiating into one of several mesenchymal phenotypes such as osteoblasts, chondrocytes, myocytes, marrow stromal cells, tendon-ligament fibroblasts, and adipocytes. In addition, these MSCs secrete a variety of cytokines and growth factors that have both paracrine and autocrine activities. These secreted bioactive factors suppress the local immune system, inhibit fibrosis (scar formation) and apoptosis, enhance angiogenesis, and stimulate mitosis and differentiation of tissue-intrinsic reparative or stem cells. These effects, which are referred to as trophic effects, are distinct from the direct differentiation of MSCs into repair tissue. Several studies which tested the use of MSCs in models of infarct (injured heart), stroke (brain), or meniscus regeneration models are reviewed within the context of MSC-mediated trophic effects in tissue repair. J. Cell. Biochem. 98: 1076–1084, 2006. © 2006 Wiley-Liss, Inc.

Key words: MSCs; stroke; meniscus; cardiac

- Opinion has shifted from differentiation ability of MSCs to the paracrine effect
- MSCs secrete a variety of cytokines and growth factors that are immuno-modulatory and trophic

Why the shift in thinking?

- MSC's in Bone Marrow
  - Stromal Cells assist HSC in differentiation, but remain as Stromal Cells
- MSC's in tissue repair studies
  - May have very little or no differentiation, despite therapeutic effect
- MSC's in Stroke and Ischaemic Heart studies – range of effects
  - Inhibit scar formation
  - Induce angiogenesis
  - Stimulate local progenitor cells to differentiate
- Meniscus study (Murphy et al 2003)

(Caplan, 2006)

ARTHRITIS & RHEUMATISM
Vol. 48, No. 12, December 2003, pp 3464–3474
DOI 10.1002/art.11365
© 2003, American College of Rheumatology

Stem Cell Therapy in a Caprine Model of Osteoarthritis

J. Mary Murphy,[1] David J. Fink,[1] Ernst B. Hunziker,[2] and Frank P. Barry[1]

Objective. **To explore the role that implanted mesenchymal stem cells may play in tissue repair or regeneration of the injured joint, by delivery of an autologous preparation of stem cells to caprine knee joints following induction of osteoarthritis (OA).**

Methods. **Adult stem cells were isolated from caprine bone marrow, expanded in culture, and transduced to express green fluorescent protein. OA was induced unilaterally in the knee joint of donor animals**

many generations, while retaining their capacity to differentiate when exposed to appropriate signals. The isolation of these cells from adult tissues raises opportunities for the development of novel cellular therapies without the ethical considerations associated with the use of embryonic stem cells. Multipotent cells have been isolated from various mesenchymal tissues in adults, including skeletal muscle, fat, and synovial membrane (11–13) as well as hematopoietic (14), neural (15), and

- Menisectomy & ACL cut in 24 goats knees
- Exercised, then Injected 6 weeks later ….
  - Study group : MSC + HA, Control group : HA alone
- 3 month, 6 month animal sacrificed

Result

- Control Group
  - Massive cartilage erosion
  - Subchondral sclerosis and osteophytes
- MSC Group
  - Evidence of Regeneration of meniscus
  - Less subchondral sclerosis
  - Less osteophytes, Less osteophytes
  - More than Differentiation Effect alone
- No effect on ACL in both groups

Journal of Pathology
J Pathol 2009; **217**: 318–324
Published online 16 October 2008 in Wiley InterScience
(www.interscience.wiley.com) **DOI:** 10.1002/path.2469

Invited Review

Why are MSCs therapeutic? New data: new insight

Al Caplan*
Skeletal Research Center, Department of Biology, Case Western Reserve University, Cleveland, OH 44106, USA

**Correspondence to:*
Al Caplan, Skeletal Research Center, Department of Biology, Case Western Reserve University, Cleveland, OH 44106, USA.
E-mail: arnold.caplan@case.edu

Conflict of interest statement: my colleagues and I started Osiris Therapeutics Inc. in late 1992. I no longer own stock in Osiris, neither do I have direct contact with the company.

Abstract

Adult marrow-derived mesenchymal stem cells (MSCs) are able to differentiate into bone, cartilage, muscle, marrow stroma, tendon–ligament, fat and other connective tissues. The questions can be asked, what do MSCs do naturally and where is the MSC niche? New insight and clinical experience suggest that MSCs are naturally found as perivascular cells, summarily referred to as pericytes, which are released at sites of injury, where they secrete large quantities of bioactive factors that are both immunomodulatory and trophic. The trophic activity inhibits ischaemia-caused apoptosis and scarring while stimulating angiogenesis and the mitosis of tissue intrinsic progenitor cells. The immunomodulation inhibits lymphocyte surveillance of the injured tissue, thus preventing autoimmunity, and allows allogeneic MSCs to be used in a variety of clinical situations. Thus, a new, enlightened era of experimentation and clinical trials has been initiated with xenogenic and allogeneic MSCs.

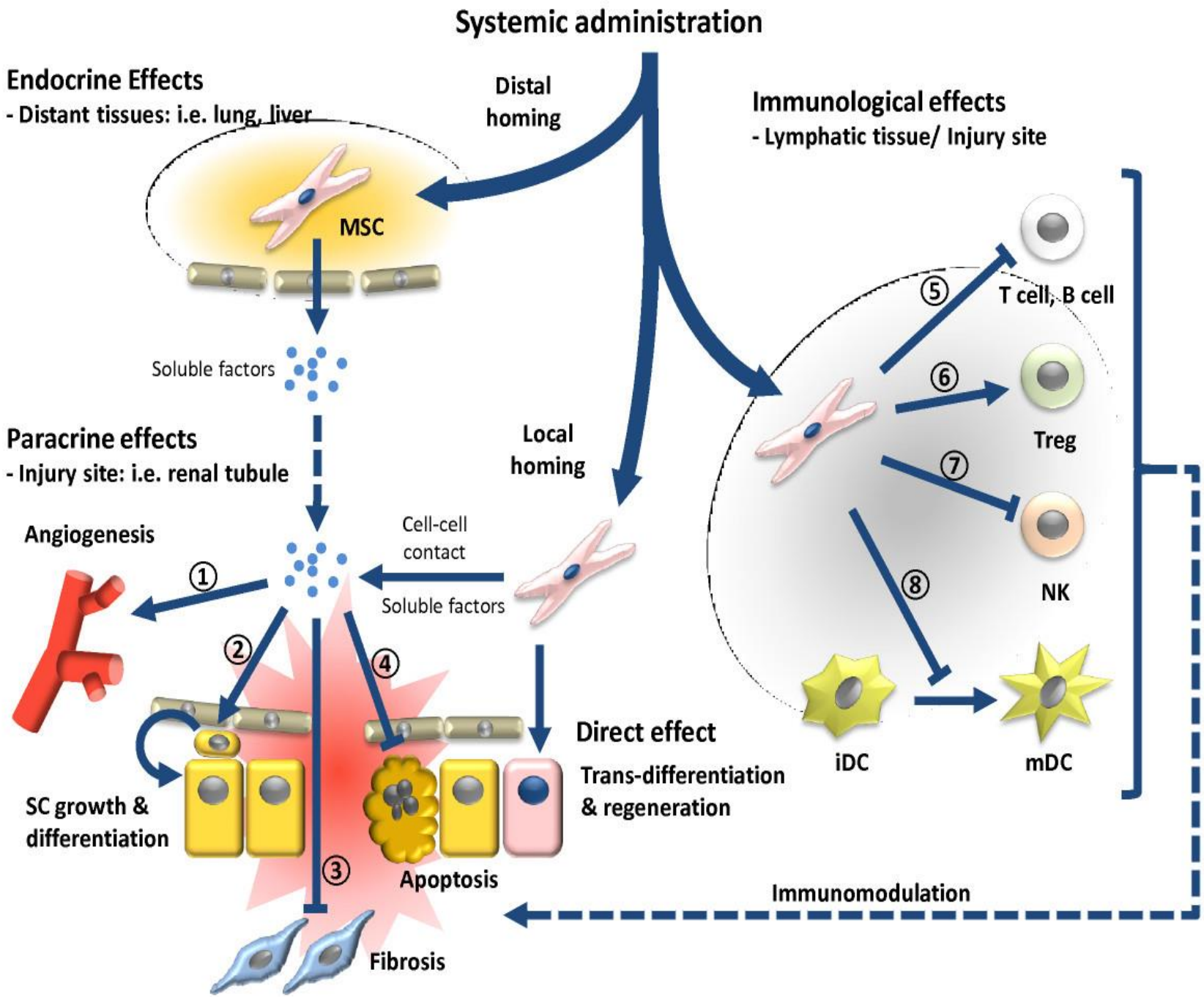
Systemic administration
Endocrine Effects
- Distant tissues: i.e. lung, liver
Distal homing
Immunological effects
- Lymphatic tissue/ Injury site
MSC
Soluble factors
T cell, B cell
Treg
NK
iDC
mDC
Paracrine effects
- Injury site: i.e. renal tubule
Local homing
Angiogenesis
Cell-cell contact
Soluble factors
Direct effect
Trans-differentiation & regeneration
SC growth & differentiation
Apoptosis
Fibrosis
Immunomodulation
①
②
③
④
⑤
⑥
⑦
⑧

The MSC: An Injury Drugstore

Arnold I. Caplan[1,*] and Diego Correa[1]
[1]Skeletal Research Center, Department of Biology, Case Western Reserve University, 10900 Euclid Avenue, Cleveland, OH 44106-7080, USA
*Correspondence: arnold.caplan@case.edu
DOI 10.1016/j.stem.2011.06.008

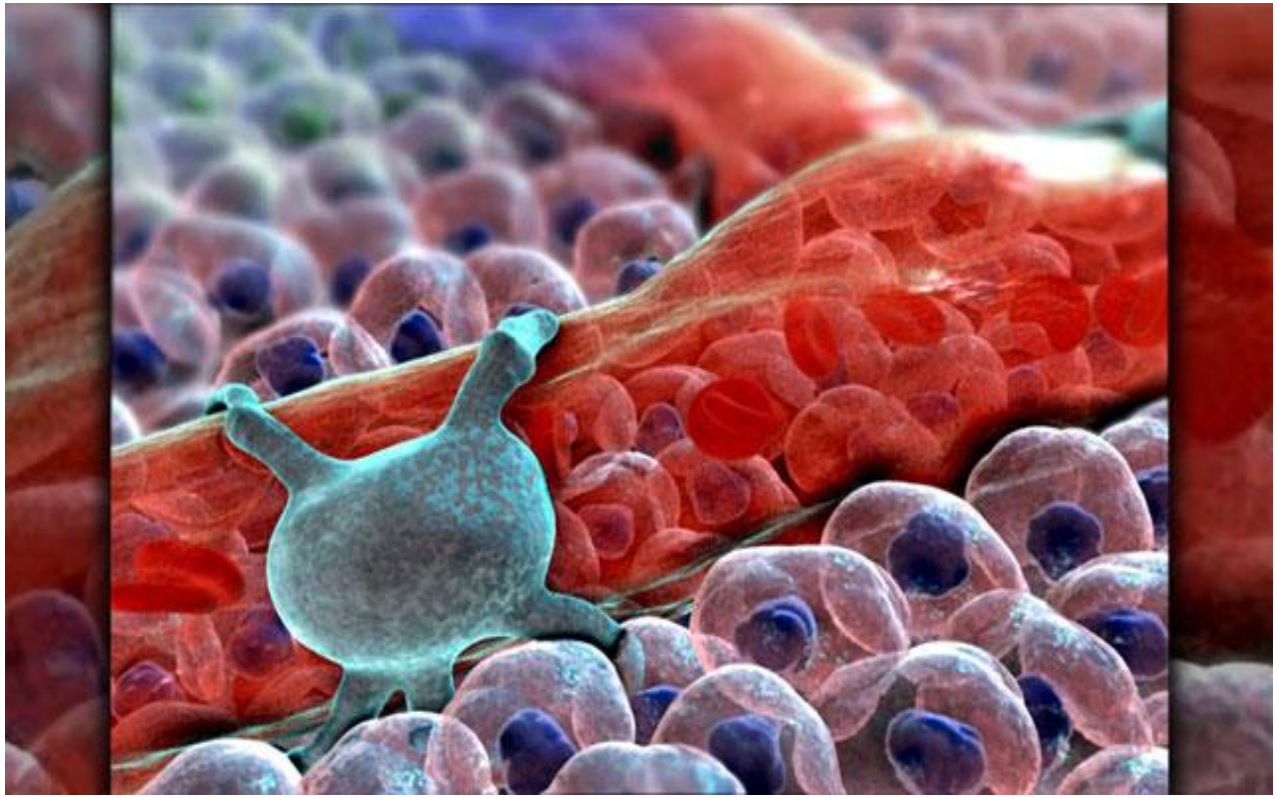

“Scientists are enormously clever in terms of the tricks we can make cells perform in the context of manipulated culture conditions. However, how to translate these tricks into successful clinical protocols has proven to be elusive.

The powerful, natural capacities of these isolated cells when put back into the body either as freshly harvested cells or after culture expansion is the more important discovery”

Caplan & Correa 2011

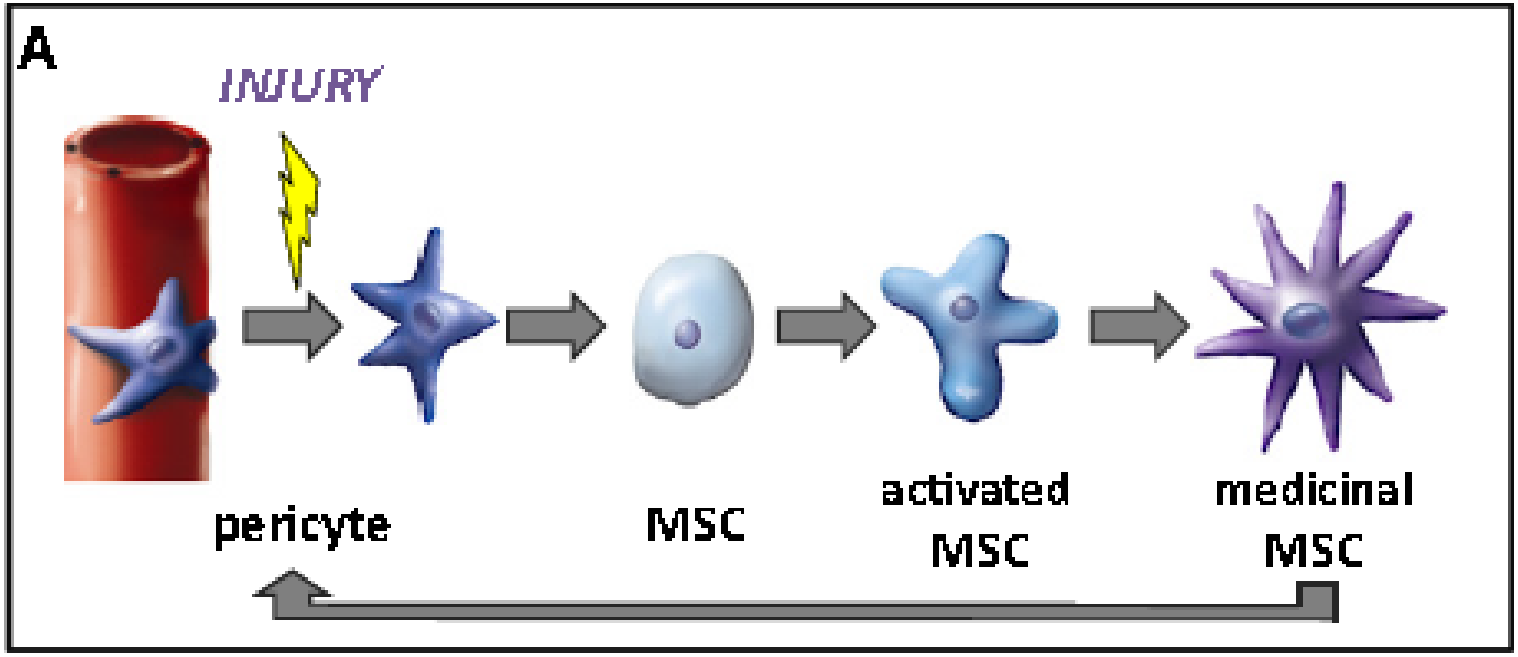
A
INJURY
pericyte
MSC
activated MSC
medicinal MSC

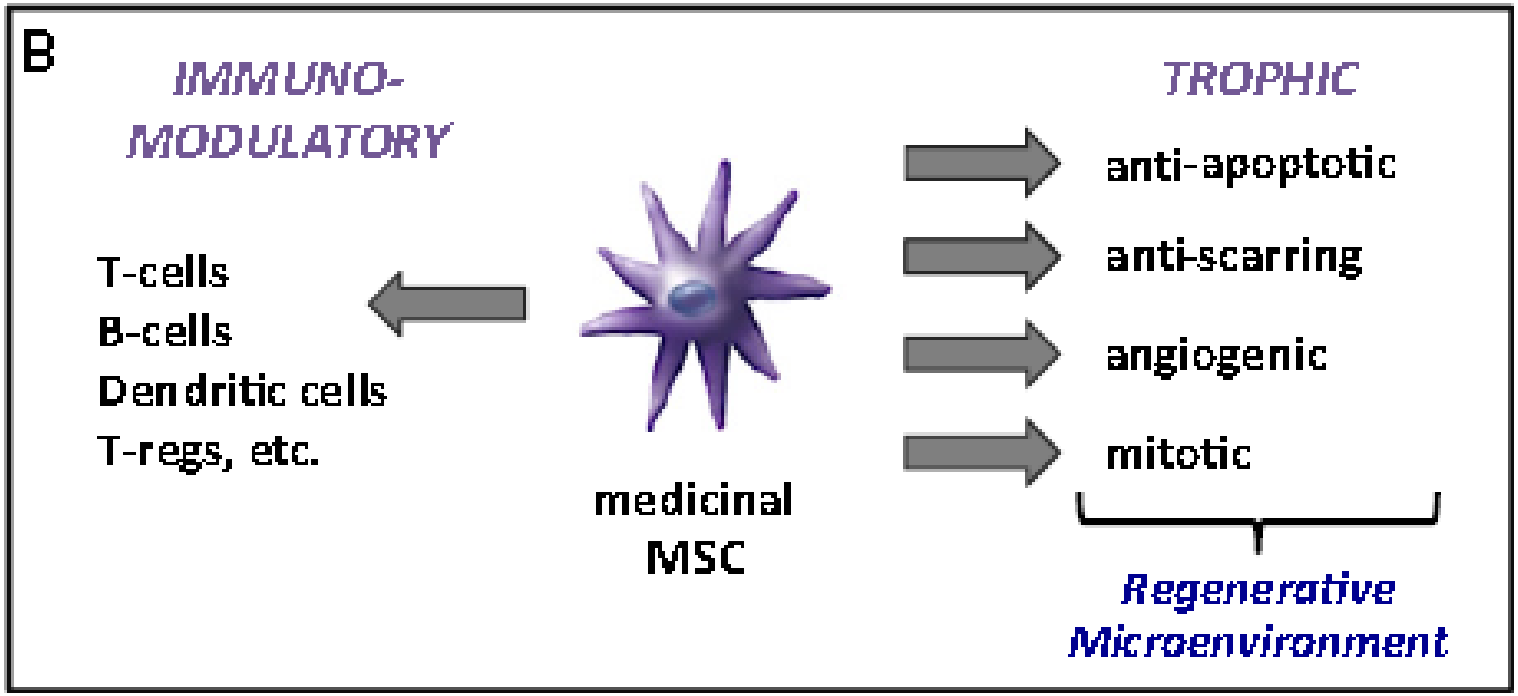
B
IMMUNO-MODULATORY
T-cells
B-cells
Dendritic cells
T-regs, etc.
medicinal MSC
TROPHIC
anti-apoptotic
anti-scarring
angiogenic
mitotic
Regenerative Microenvironment

What do MSC's normally do in the body?

MSCs and their secretions have been shown to:

- Reduce inflammation
- Inhibit scar formation
- Protect cells in damaged tissue
- Stimulate the growth of new blood vessels
- Promote wound healing
- Stimulate local progenitor cells

Major Safety Studies

Centeno (2010)

- 227 patients. Knee, Back and Hips. 2 year follow-up
- No tumors, no joint infections

Lalu (2010)

- Systematic review of Mesenchymal Stem Cell treatment. 24 studies, 652 patients
- *"MSC administration appears to be safe based on the available evidence"*

Wakitani (2011)

- 41 patients. Knee OA. 11 year follow-up
- No cancer, no infections

Safety of Cell Therapy with Mesenchymal Stromal Cells (SafeCell): A Systematic Review and Meta-Analysis of Clinical Trials

Manoj M. Lalu[1,5], Lauralyn McIntyre[2,5*], Christina Pugliese[5], Dean Fergusson[5], Brent W. Winston[6], John C. Marshall[7], John Granton[8], Duncan J. Stewart[3,4], for the Canadian Critical Care Trials Group

1 Department of Anesthesiology, University of Ottawa, Ottawa, Canada, 2 Department of Medicine (Division of Critical Care), University of Ottawa, Ottawa, Canada, 3 Regenerative Medicine Program, The Ottawa Hospital Research Institute, Ottawa, Canada, 4 Department of Cell and Molecular Medicine, University of Ottawa, Ottawa, Canada, 5 The Ottawa Hospital Research Institute, Clinical Epidemiology Program, Ottawa, Canada, 6 Department of Critical Care Medicine, University of Calgary, Calgary, Canada, 7 Department of Surgery (Critical Care), University of Toronto, Toronto, Canada, 8 Department of Medicine (Critical Care), University of Toronto, Toronto, Canada

Abstract

Background: Mesenchymal stromal cells (MSCs, "adult stem cells") have been widely used experimentally in a variety of clinical contexts. There is interest in using these cells in critical illness, however, the safety profile of these cells is not well known. We thus conducted a systematic review of clinical trials that examined the use MSCs to evaluate their safety.

Methods and Findings: MEDLINE, EMBASE, and the Cochrane Central Register of Controlled Trials (to June 2011), were searched. Prospective clinical trials that used intravascular delivery of MSCs (intravenously or intra-arterially) in adult populations or mixed adult and pediatric populations were identified. Studies using differentiated MSCs or additional cell types were excluded. The primary outcome adverse events were grouped according to immediate events (acute infusional toxicity, fever), organ system complications, infection, and longer term adverse events (death, malignancy). 2347 citations were reviewed and 36 studies met inclusion criteria. A total of 1012 participants with clinical conditions of ischemic stroke, Crohn's disease, cardiomyopathy, myocardial infarction, graft versus host disease, and healthy volunteers were included. Eight studies were randomized control trials (RCTs) and enrolled 321 participants. Meta-analysis of the RCTs did not detect an association between acute infusional toxicity, organ system complications, infection, death or malignancy. There was a significant association between MSCs and transient fever.

Conclusions: Based on the current clinical trials, MSC therapy appears safe. However, further larger scale controlled clinical trials with rigorous reporting of adverse events are required to further define the safety profile of MSCs.

JOURNAL OF TISSUE ENGINEERING AND REGENERATIVE MEDICINE
J Tissue Eng Regen Med 2011; 5: 146–150.
Published online 6 July 2010 in Wiley Online Library (wileyonlinelibrary.com) DOI: 10.1002/term.299

RESEARCH ARTICLE

Safety of autologous bone marrow-derived mesenchymal stem cell transplantation for cartilage repair in 41 patients with 45 joints followed for up to 11 years and 5 months

Shigeyuki Wakitani[1]*, Takahiro Okabe[1], Shuji Horibe[2], Tomoki Mitsuoka[2], Masanobu Saito[3], Tsuyoshi Koyama[3], Masashi Nawata[4], Keiji Tensho[4], Hiroyuki Kato[4], Kota Uematsu[5], Ryosuke Kuroda[6], Masahiro Kurosaka[6], Shinichi Yoshiya[7], Koji Hattori[8] and Hajime Ohgushi[8]
[1]*Department of Orthopaedic Surgery, Osaka City University Graduate School of Medicine, Japan*
[2]*Department of Orthopaedic Surgery, Osaka Rosai Hospital, Japan*
[3]*Department of Orthopaedic Surgery, National Hospital Organization, Osaka Minami Medical Centre, Japan*
[4]*Department of Orthopaedic Surgery, Shinshu University, Japan*
[5]*Department of Orthopaedic Surgery, Nara Medical University, Japan*
[6]*Department of Orthopaedic Surgery, Kobe University Graduate School of Medicine, Japan*
[7]*Department of Orthopaedic Surgery, Hyogo College of Medicine, Japan*
[8]*Research Institute for Cell Engineering, Advanced Industrial Science and Technology, Amagasaki site, Kansai, Japan*

Abstract

Among autologous somatic stem cells, bone marrow-derived mesenchymal stem cells (BMSCs) are the most widely used worldwide to repair not only mesenchymal tissues (bone, cartilage) but also many other kinds of tissues, including heart, skin, and liver. Autologous BMSCs are thought to be safe because of the absence of immunological reaction and disease transmission. However, it is possible that they will form tumours during long-term follow-up. In 1988, we transplanted autologous BMSCs to repair articular cartilage, which was the first such trial ever reported. Subsequently we performed this procedure in about 40 patients. Demonstration that neither partial infections nor tumours appeared in these patients provided strong evidence for the safety of autologous BMSC transplantation. Thus, in this study we checked these patients for tumour development and infections. Between January 1998 and November 2008, 41 patients received 45 transplantations. We checked their records until their last visit. We telephoned or mailed the patients who had not visited the clinics recently to establish whether there were any abnormalities in the operated joints. Neither tumours nor infections were observed between 5 and 137 (mean 75) months of follow-up. Autologous BMSC transplantation is a safe procedure and will be widely used around the world.
Copyright © 2010 John Wiley & Sons, Ltd.

Fat-derived MSC Pilot in Humans

Mesenchymal Stem Cell Injections Improve Symptoms of Knee Osteoarthritis

Yong-Gon Koh, M.D., Seung-Bae Jo, M.D., Oh-Ryong Kwon, M.D., Dong-Suk Suh, M.D., Seung-Woo Lee, M.D., Sung-Ho Park, M.D., and Yun-Jin Choi, M.D.

Purpose: The purpose of this study was to evaluate the clinical and imaging results of patients who received intra-articular injections of autologous mesenchymal stem cells for the treatment of knee osteoarthritis. **Methods:** The study group comprised 18 patients (6 men and 12 women), among whom the mean age was 54.6 years (range, 41 to 69 years). In each patient the adipose synovium was harvested from the inner side of the infrapatellar fat pad by skin incision extension at the arthroscopic lateral portal site after the patient underwent arthroscopic debridement. After stem cells were isolated, a mean of 1.18×10^6 stem cells (range, 0.3×10^6 to 2.7×10^6 stem cells) were prepared with approximately 3.0 mL of platelet-rich plasma (with a mean of 1.28×10^6 platelets per microliter) and injected into the selected knees of patients. Clinical outcome was evaluated with the Western Ontario and McMaster Universities Osteoarthritis Index, the Lysholm score, and the visual analog scale (VAS) for grading knee pain. We also compared magnetic resonance imaging (MRI) data collected both preoperatively and at the final follow-up. **Results:** Western Ontario and McMaster Universities Osteoarthritis Index scores decreased significantly ($P < .001$) from 49.9 points preoperatively to 30.3 points at the final follow-up (mean follow-up, 24.3 months; range, 24 to 26 months). Lysholm scores also improved significantly ($P < .001$) by the last follow-up visit, increasing from a mean preoperative value of 40.1 points to 73.4 points by the end of the study. Likewise, changes in VAS scores throughout the follow-up period were also significant ($P = .005$); the mean VAS score decreased from 4.8 preoperatively to 2.0 at the last follow-up visit. Radiography showed that, at the final follow-up point, the whole-organ MRI score had significantly improved from 60.0 points to 48.3 points ($P < .001$). Particularly notable was the change in cartilage whole-organ MRI score, which improved from 28.3 points to 21.7 points ($P < .001$). Further analysis showed that improvements in clinical and MRI results were positively related to the number of stem cells injected. **Conclusions:** The results of our study are encouraging and show that intra-articular injection of infrapatellar fat pad–derived mesenchymal stem cells is effective for reducing pain and improving knee function in patients being treated for knee osteoarthritis. **Level of Evidence:** Level IV, therapeutic case series.

Koh al (2012), Journal of Arthroscopy

Summary:

- 18 patients
- Adipose MSCs (synovium of infrapatella fat pad)
- mixed with 3ml of PRP

Primary Outcomes:

- WOMAC index, Lysholm score, VAS

Secondary Outcomes:

- MRI

Outcomes

	Preoperative Status (Mean ± SD)	Last Follow-up (Mean ± SD)	*P* Value*
WOMAC score	49.9 ± 12.6	**30.3 ± 9.2**	<.001
Lysholm score	40.1 ± 12.1	**73.4 ± 13.5**	<.001
VAS score	4.8 ± 1.6	**2.0 ± 1.1**	<.001

NOTE. Boldface indicates pertinent results.
*Determined by Wilcoxon signed rank test.

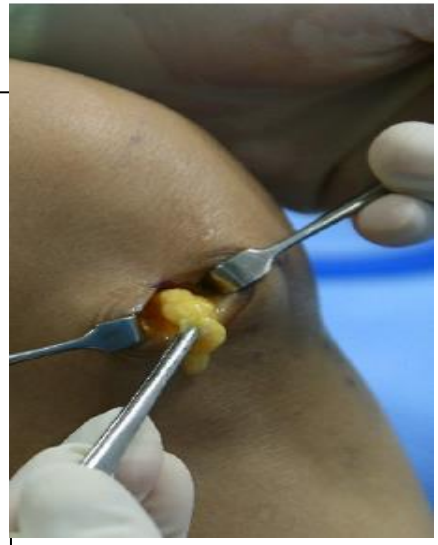

- Mean follow-up: 24.3 months
- All clinical and radiological scores improved significantly at last review
- Improvements in clinical and MRI results were positively related to the number of stem cells injected

Fat-derived MSCs with arthroscopy

Knee Surg Sports Traumatol Arthrosc
DOI 10.1007/s00167-013-2807-2

KNEE

Clinical results and second-look arthroscopic findings after treatment with adipose-derived stem cells for knee osteoarthritis

Yong-Gon Koh · Yun-Jin Choi · Sae-Kwang Kwon · Yong-Sang Kim · Jee-Eun Yeo

Abstract
Purpose In the present study, the clinical outcomes and second-look arthroscopic findings of intra-articular injection of stem cells with arthroscopic lavage for treatment of elderly patients with knee osteoarthritis (OA) were evaluated.
Methods Stem cell injections combined with arthroscopic lavage were administered to 30 elderly patients (≥65 years) with knee OA. Subcutaneous adipose tissue was harvested from both buttocks by liposuction. After stromal vascular fractions were isolated, a mean of 4.04×10^6 stem cells (9.7 % of 4.16×10^7 stromal vascular fraction cells) were prepared and injected in the selected knees of patients after arthroscopic lavage. Outcome measures included the Knee Injury and Osteoarthritis Outcome Scores, visual analog scale, and Lysholm score at preoperative and 3-, 12-, and 2-year follow-up visits. Sixteen patients underwent second-look arthroscopy.
Results Almost all patients showed significant improvement in all clinical outcomes at the final follow-up examination. All clinical results significantly improved at 2-year follow-up compared to 12-month follow-up ($P < 0.05$). Among elderly patients aged >65 years, only five patients demonstrated worsening of Kellgren–Lawrence grade. On second-look arthroscopy, 87.5 % of elderly patients (14/16) improved or maintained cartilage status at least 2 years postoperatively. Moreover, none of the patients underwent total knee arthroplasty during this 2-year period.
Conclusion Adipose-derived stem cell therapy for elderly patients with knee OA was effective in cartilage healing, reducing pain, and improving function. Therefore, adipose-derived stem cell treatment appears to be a good option for OA treatment in elderly patients.
Level of evidence Therapeutic case series study, Level IV.

Keywords Mesenchymal stem cell · Arthroscopic lavage · Knee osteoarthritis

Introduction

Osteoarthritis (OA) is the most common musculoskeletal disorder [3]. Synovial inflammation, in particular, can affect joint homoeostasis [5] and is associated with pain and OA disease progression [31]. The current treatments for OA are not regenerative and have little impact on the progressive degeneration of joint tissues. Clinical interventions are primarily symptomatic and focus on pain reduction and inflammation control through nonsteroidal anti-inflammatory drugs and ultimately with total joint replacement [4]. Few options are currently available for elderly patients with moderate to severe arthritis. Most approaches are palliative and address symptoms rather than influencing the biochemical environment of the joint or disease process.

Koh al (2013)Knee Surgery Sports Traumatology Arthroscopy

Summary:

- 30 patients (elderly 65 years)
- Adipose MSCs (buttocks)
- 4M MSCs (mean) after arthroscopy (MSCs mixed with 3.0ml of PRP)
- 16 patients – 2nd look arthroscopy @ 2 years

Primary Outcomes:

- KOOS, VAS and Lysholm score

Secondary Outcomes:

- 2nd look arthroscopy

Outcomes

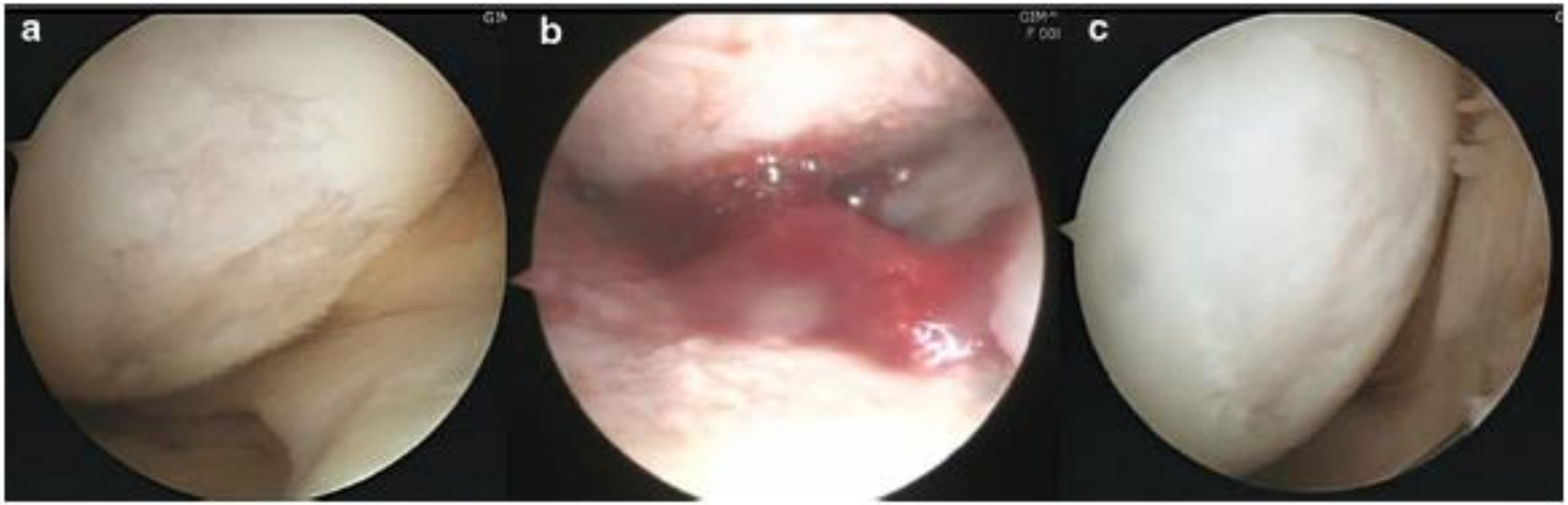

- All clinical results significantly improved at 2-year compared to 1-year follow-up ($P < 0.05$)
- 2nd look arthroscopy: 14/16 improved or maintained cartilage status at least 2 years postoperatively
- No patient underwent TKR during this 2-year period

Fat-derived MSC Injection Pilot

STEM CELLS®

TRANSLATIONAL AND CLINICAL RESEARCH

Intra-articular Injection of Mesenchymal Stem Cells for the Treatment of Osteoarthritis of the Knee: A Proof-of-Concept Clinical Trial

Chris Hyunchul Jo[1], Young Gil Lee[1], Won Hyoung Shin[1], Hyang Kim[1], Jee Won Chai[2], Eui Cheol Jeong[3], Ji Eun Kim[4], Hackjoon Shim[5], Ji Sun Shin[1], Il Seob Shin[6], Jeong Chan Ra[6], Sohee Oh[7], and Kang Sup Yoon[1*]

[1]Department of Orthopedic Surgery, [2]Department of Radiology, [3]Department of Plastic and Reconstructive Surgery, [4]Department of Pathology, Seoul National University College of Medicine, SMG-SNU Boramae Medical Center, 20 Boramae-ro 5-gil, Dongjak-gu, Seoul 156-707, Korea; [5]Cardiovascular Research Institute, Yonsei University College of Medicine, 250 Seongsanno, Seodaemung-gu, Seoul, 120-752, Korea; [6]Stem Cell Research Center, K-STEM CELL, 1596-7 Nakseongdae-dong, Gwanak-gu, Seoul, 151-835, Korea; [7]Department of Biostatistics, SMG-SNU Boramae Medical Center, Seoul, Korea.

Key words. Osteoarthritis • adipose-tissue derived mesenchymal stem cells • intra-articular injection • cartilage regeneration

ABSTRACT

Mesenchymal stem cells are known to have a potential for articular cartilage regeneration. However, most studies focused on focal cartilage defect through surgical implantation. For the treatment of generalized cartilage loss in osteoarthritis, an alternative delivery strategy would be more appropriate. The purpose of this study was to assess the safety and efficacy of intra-articular injection of autologous adipose tissue derived MSCs (AD-MSCs) for knee osteoarthritis. We enrolled 18 patients with osteoarthritis of the knee and injected AD MSCs into the knee. The phase I study consists of 3 dose-escalation cohorts; the low-dose ($1.0x10^7$ cells), mid-dose ($5.0x10^7$) and high-dose ($1.0x10^8$) group with 3 patients each. The phase II included 9 patients receiving the high-dose. The primary outcomes were the safety and the Western Ontario and McMaster Universities Osteoarthritis index (WOMAC) at 6 months. Secondary outcomes included clinical, radiological, arthroscopic, and histological evaluations. There was no treatment-related adverse event. The WOMAC score improved at 6 months after injection in the high-dose group. The size of cartilage defect decreased while the volume of cartilage increased in the medial femoral and tibial condyles of the high-dose group. Arthroscopy showed that the size of cartilage defect decreased in the medial femoral and medial tibial condyles of the high-dose group. Histology demonstrated thick, hyaline-like cartilage regeneration. These results showed that intra-articular injection of $1.0x10^8$ AD MSCs into the osteoarthritic knee improved function and pain of the knee joint without causing adverse events, and reduced cartilage defects by regeneration of hyaline-like articular cartilage.

Jo al (2013) Translational and Clinical Research

Summary:

- 18 patients
- Adipose derived MSCs
- 3 groups – 1M x MSCs, 5M x MSCs and 10M x MSCs
- 16 patients – 2nd look arthroscopy

Primary Outcomes:

- Safety and WOMAC

Secondary Outcomes:

- Radiology, Arthroscopy and Histology

Outcomes

Jo al (2013)

Safety:
No apparent adverse events

Clinical Efficacy:
- Improved knee function (6 months)
- 10M x MSC group – 30% pain reduction at 6 months vs baseline

MRI and 2nd look arthroscopy:
- 10M MSC group – showed significantly regenerated articular cartilage

Histology:
- Regenerated cartilage was thick, had a glossy white matrix and smooth surface
- Cartilage was well integrated with subchondral bone

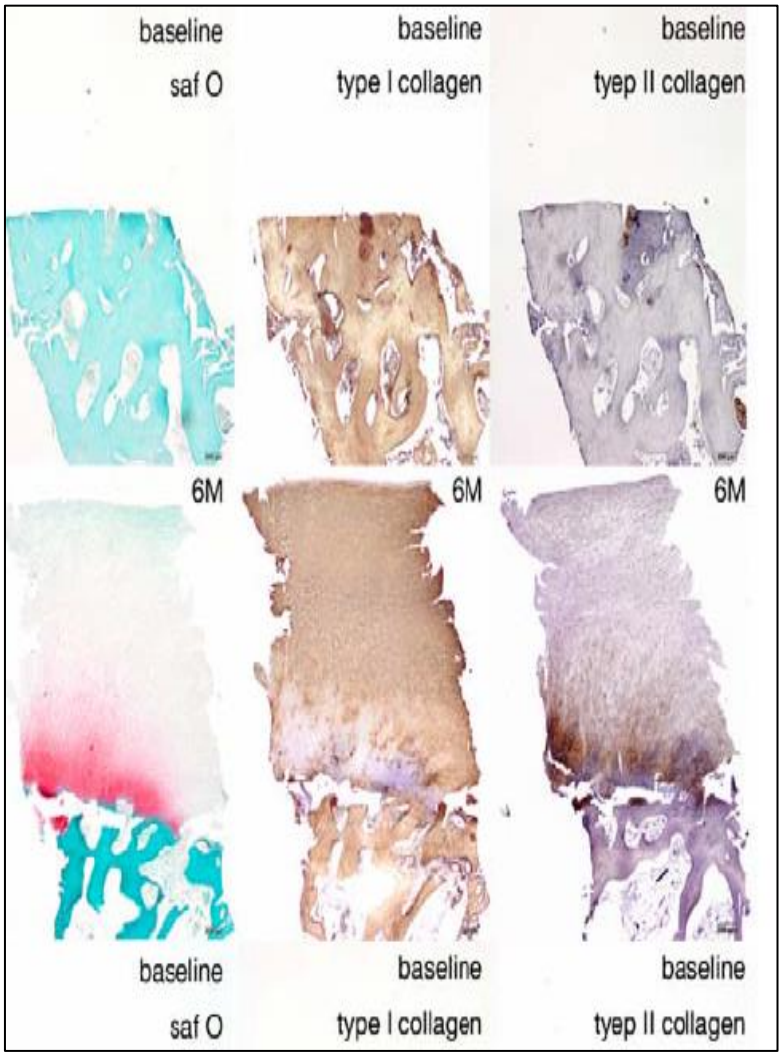

Multi Centre RCT - Bone Marrow MSCs

COPYRIGHT © 2014 BY THE JOURNAL OF BONE AND JOINT SURGERY, INCORPORATED

Adult Human Mesenchymal Stem Cells Delivered via Intra-Articular Injection to the Knee Following Partial Medial Meniscectomy

A Randomized, Double-Blind, Controlled Study

C. Thomas Vangsness Jr., MD, Jack Farr II, MD, Joel Boyd, MD, David T. Dellaero, MD, C. Randal Mills, PhD, and Michelle LeRoux-Williams, PhD

Investigation performed at the University of Southern California Orthopaedic Surgery Associates, Keck School of Medicine, Los Angeles, California, Unlimited Research, San Antonio, Texas, Triangle Orthopaedic Associates, Durham, North Carolina, Orthopaedic Center of Vero Beach, Vero Beach, Florida, OrthoIndy, Indianapolis, Indiana, TRIA Orthopaedic Center, Bloomington Minnesota, and Greater Chesapeake Orthopaedic Associates, Baltimore, Maryland

Background: There are limited treatment options for tissue restoration and the prevention of degenerative changes in the knee. Stem cells have been a focus of intense preclinical research into tissue regeneration but limited clinical investigation. In a randomized, double-blind, controlled study, the safety of the intra-articular injection of human mesenchymal stem cells into the knee, the ability of mesenchymal stem cells to promote meniscus regeneration following partial meniscectomy, and the effects of mesenchymal stem cells on osteoarthritic changes in the knee were investigated.

Methods: A total of fifty-five patients at seven institutions underwent a partial medial meniscectomy. A single superolateral knee injection was given within seven to ten days after the meniscectomy. Patients were randomized to one of three treatment groups: Group A, in which patients received an injection of 50×10^6 allogeneic mesenchymal stem cells; Group B, 150×10^6 allogeneic mesenchymal stem cells; and the control group, a sodium hyaluronate (hyaluronic acid/hyaluronan) vehicle control. Patients were followed to evaluate safety, meniscus regeneration, the overall condition of the knee joint, and clinical outcomes at intervals through two years. Evaluations included sequential magnetic resonance imaging (MRI).

Results: No ectopic tissue formation or clinically important safety issues were identified. There was significantly increased meniscal volume (defined a priori as a 15% threshold) determined by quantitative MRI in 24% of patients in Group A and 6% in Group B at twelve months post meniscectomy ($p = 0.022$). No patients in the control group met the 15% threshold for increased meniscal volume. Patients with osteoarthritic changes who received mesenchymal stem cells experienced a significant reduction in pain compared with those who received the control, on the basis of visual analog scale assessments.

Conclusions: There was evidence of meniscus regeneration and improvement in knee pain following treatment with allogeneic human mesenchymal stem cells. These results support the study of human mesenchymal stem cells for the apparent knee-tissue regeneration and protective effects.

Vangness et al (2014)

Publication: The Journal of Bone and Joint Surgery

Summary:

- 55 patients
- 7 different US institutions
- Bone marrow MSCs give 7-10 days post arthroscopy
- 3 groups – 50M x MSCs, 150M x MSCs and pcontrol (HA)

Outcomes:

- Pain
- MRI - Meniscal tissue regrowth (>15%)

Outcomes

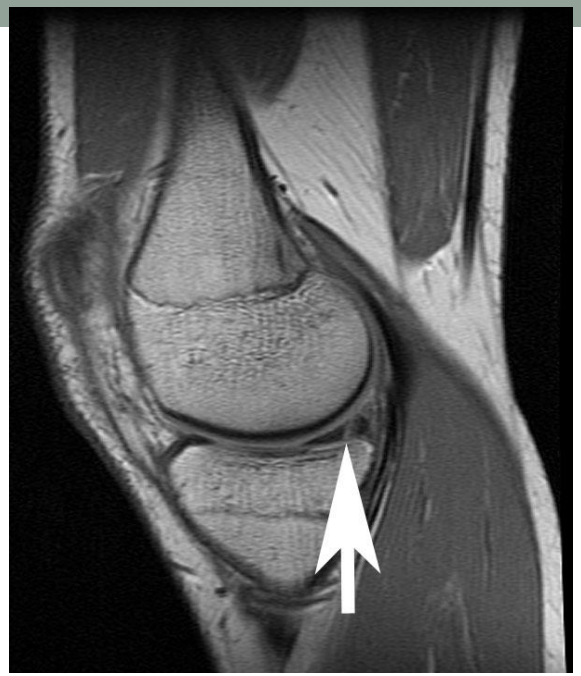

Safety:
No ectopic tissue

Pain:
- Patients with OA had pain reductions in the MSC groups (none experienced in the placebo group)
- 150M x MSC group – 30% pain reduction at 6 months vs baseline

MRI:
- 12 months post menisectomy – Significant increases in meniscal volume (>15%) for 24% patients in 50M MSC group and 6% in 150M MSC group
- No patient in control group met threshold of >15% meniscal volume increases

Subscribe and get WEEKEND PAPER DELIVERY* *Conditions apply
Daily Telegraph+ Find out more

Stem cell injections resurrect Cronulla Shark Anthony Tupou's career

TYSON OTTO THE DAILY TELEGRAPH FEBRUARY 29, 2012 12:00AM

SHARE SAVE THIS STORY

Career saved: Cronulla Shark Anthony Tupou. Picture: Gregg Porteous

A "MIRACLE" cutting-edge stem cell operation could have saved Sharks forward Anthony Tupou's career.

It sounds like something from the future, but it has the potential to transform the careers of countless NRL players right now.

Former Aussie Test second-rower Tupou became one of the first NRL players to undergo the experimental Regeneus HiQ cell procedure in October and the 28-year-old is now feeling fitter than he has in three years.

AFL approves use of Regeneus Ltd's (ASX:RGS) Stem Cell Therapy, HiQCell(R) for Injured Players

Press Release: ABN Newswire – Wed, Aug 27, 2014 11:15 AM AEST

Recommend Tweet Share Print

Companies: Regeneus Ltd

RELATED QUOTES

Symbol	Price	Change
RGS.AX	0.15	+0.01

Sydney, Australia, Aug 27, 2014 - (ABN Newswire) - Regeneus Ltd (ASX:RGS.AX - News) announced today that the Australian Football League (AFL) has granted caseby-case approval for the use of its innovative stem cell therapy, HiQCell(R) as a treatment option for injured AFL players, typically including impact related osteoarthritis and tendonitis.



- **“HiQCells”**
- Largest Registry for patients treated with ASC’s for OA and Tendinopathy
- OSCARS Trial


Lipid
Adipocytes
Saline
SVF

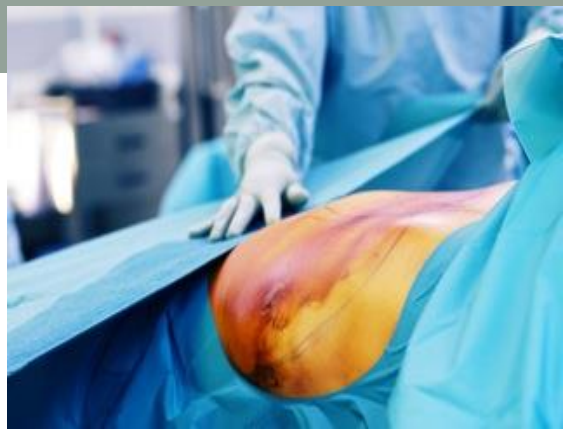

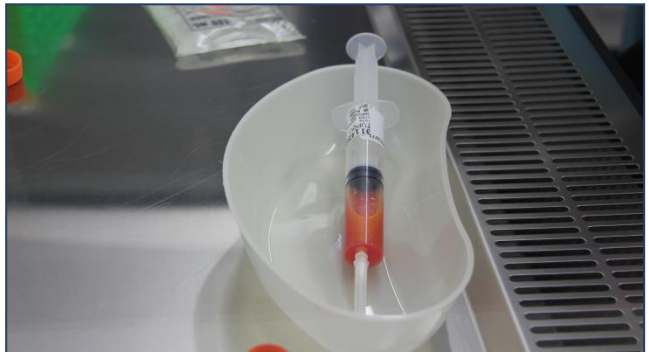

HiQCells Clinical Registry

Summary of patients and joints treated (May-2011 to 21-Jul-2014)		
	Number of patients	Number of joints/tendons
HiQCell Treatments	494	1097
HiQCell Joint Registry	386	910

78% of patients treated with HiQCell entered the Joint Registry

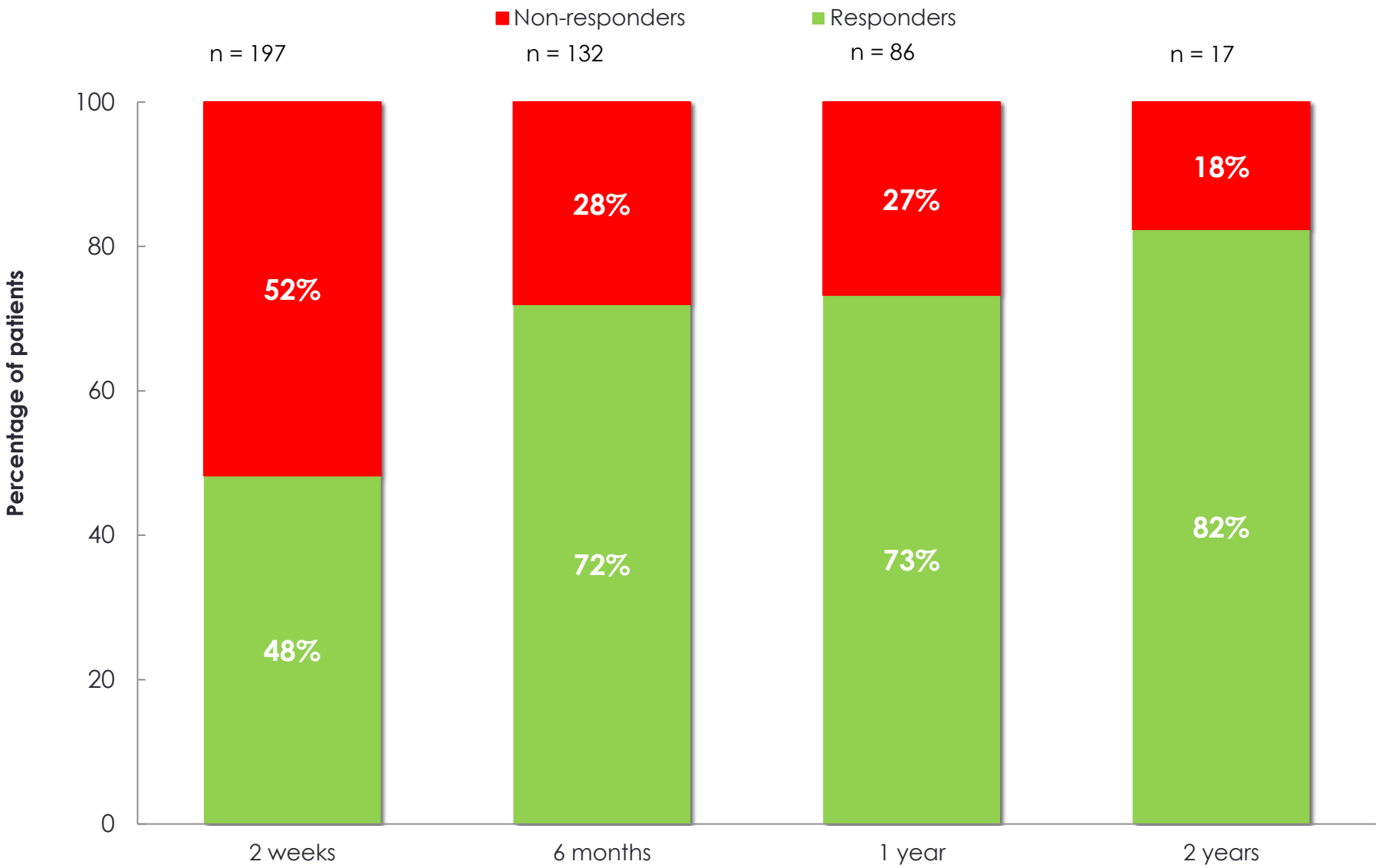

Figure 1a. Responders to treatment
Responder = >30% pain reduction from baseline

Responders percentage pain reduction

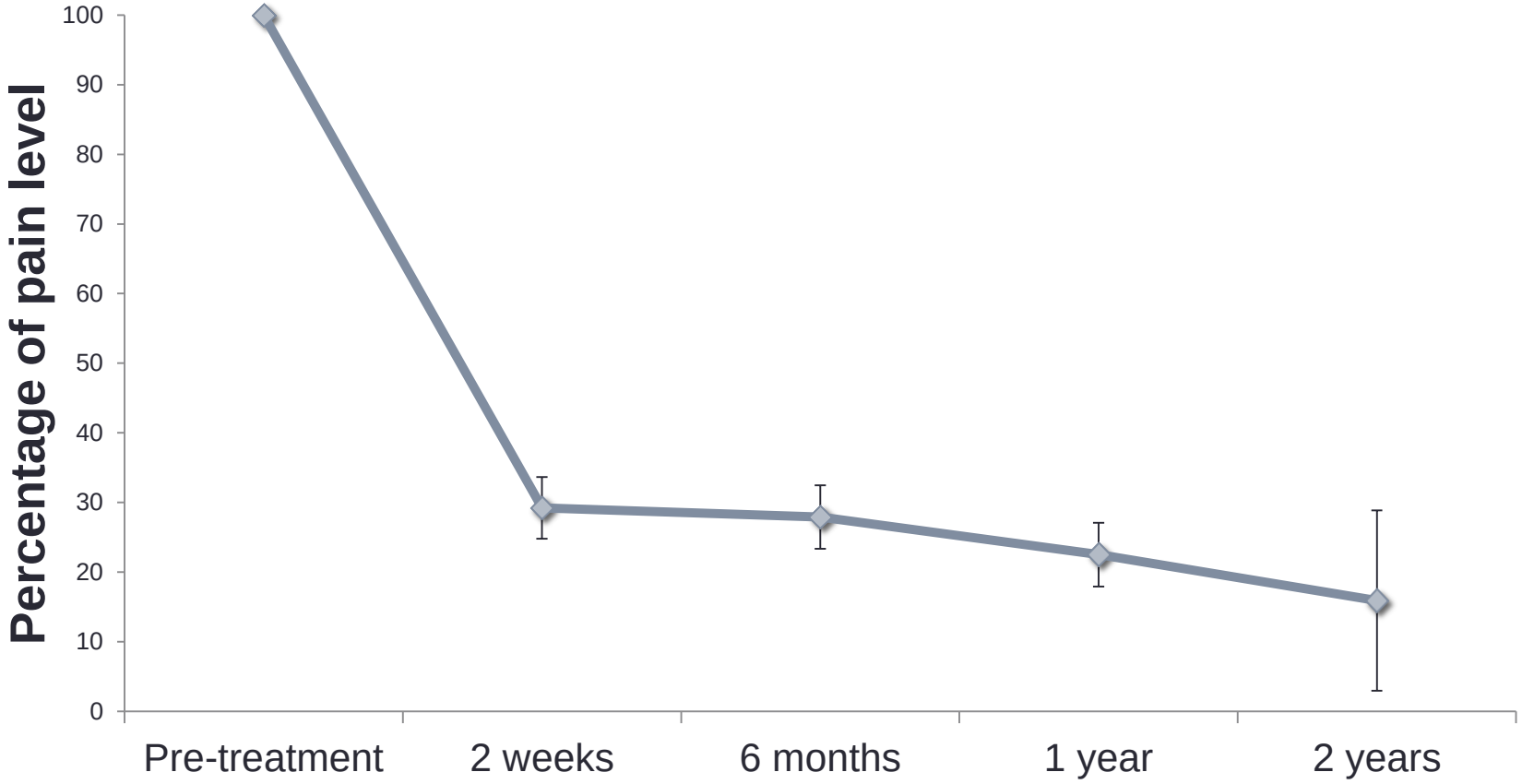

Figure 1b: Percentage pain reduction for responders (95% CI)

Responder = 30% or more pain reduction from baseline

$p < 0.0001$ at all timepoints

Medication level

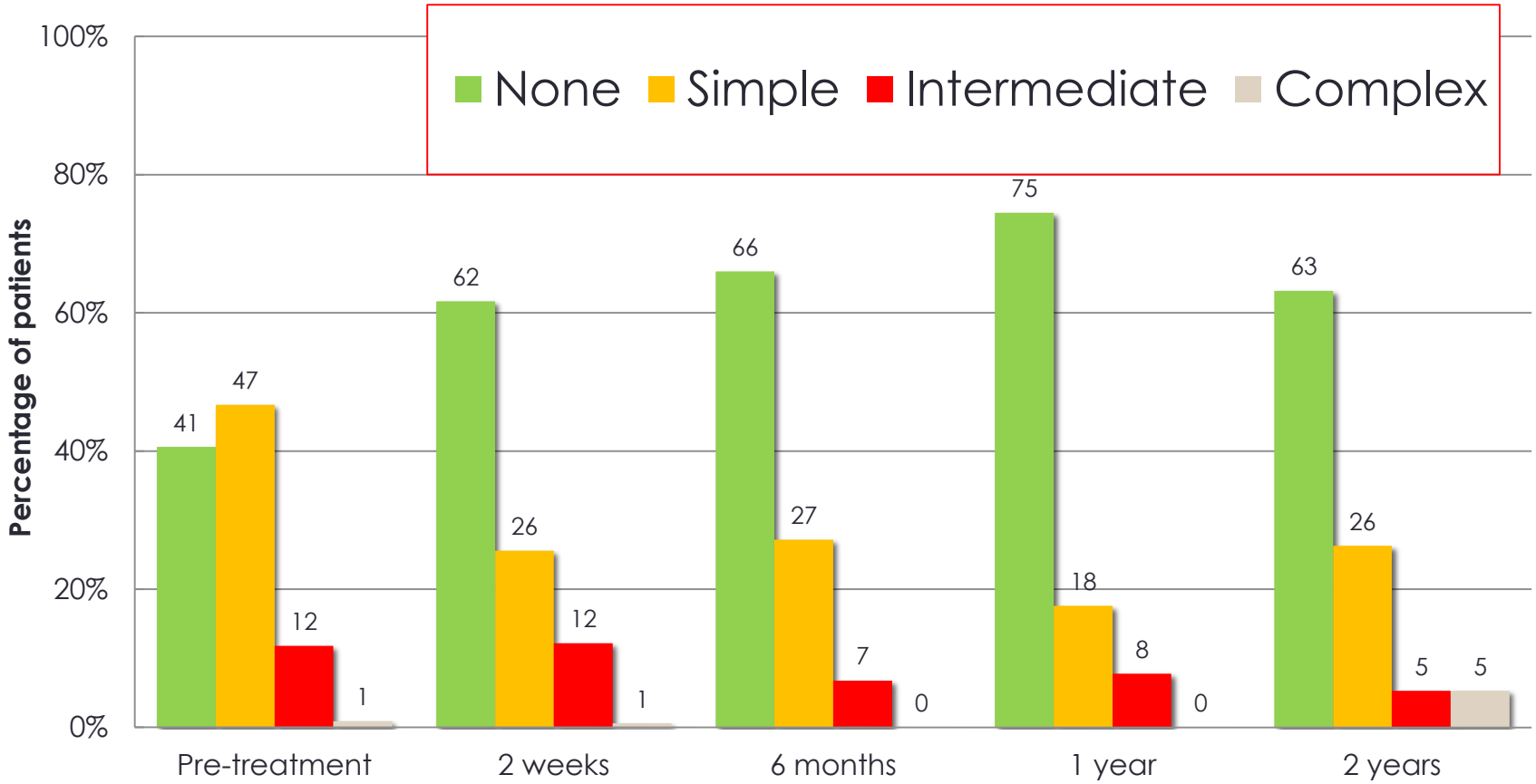

At 1-year post-treatment, an additional 34% of patients had stopped taking pain medication

RCT on HiQCell for Osteoarthritis

Osteoarthritis Stem Cell Advanced Research Study (OSCARS)

- Professor Lyn March & David Hunter, Royal North Shore Hospital
- Ethics approved,Randomised (20:20), double-blind placebo-controlled trial
- IA injection of saline vs. HiQCell
- Inclusion criteria:
    - >40 years of age
    - Diagnosed knee OA
    - Grade 1 or 2 with radiographic JSN in either medial or lateral compartments and/or osteophyte grade 2 or 3 in medial or lateral compartment without JSN
    - Symptomatic knee pain of at least 4 on NRS

OSCARS Outcomes

- The treatment was well tolerated and there were no major medium-term safety concerns.
- All patients (Treatment and Control) experienced pain reduction
- The loss of cartilage as seen on MRI was slower than expected at 6 months with HiQCells
- Objective markers of cartilage degradation (MMIF and CTX-II) suggest that HiQCell may slow the progression of OA and produce improved outcomes in the longer term.

OA Biomarkers

- **Macrophage migration inhibitory factor (MMIF)**
  - Stimulates production of cartilage degrading enzymes
  - Highly correlated with OA
  - **Lowered in HiQCell group at both 4 and 24 weeks (P=0.00), but not in control.**

- **Urinary CTX II – cartilage specific collagen fragment**
  - From breakdown of cartilage
  - Increased 31% in control (P=0.04),
  - **No increase in HiQCell Group.**
  - Biggest effect in grade 4 patients

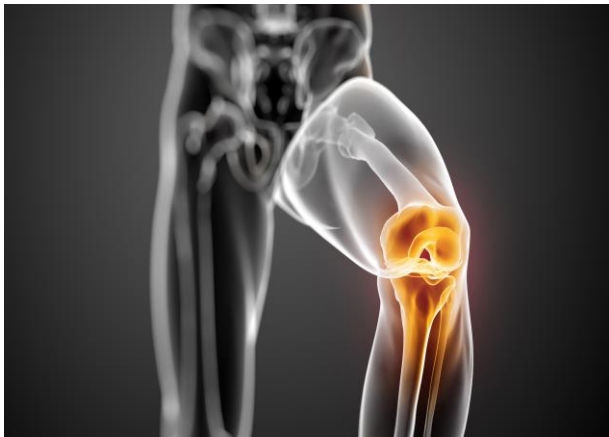

Annals of the Rheumatic Diseases

BMJ

Urinary CTX-II levels are associated with radiographic subtypes of osteoarthritis in hip, knee, hand, and facet joints in subject with familial osteoarthritis at multiple sites: the GARP study

I Meulenbelt, M Kloppenburg, [...], and P E Slagboom

Additional article information

Possible Roles for stem cells in Athletes

- For cartilage injuries (traumatic) which may be career limiting or career ending
- For meniscus injuries
- For degenerative tendon injuries
- “Vaccine” - ? Preventive role for cartilage injury in specifically loaded joints
- No current issues with doping – but cause for future concern?

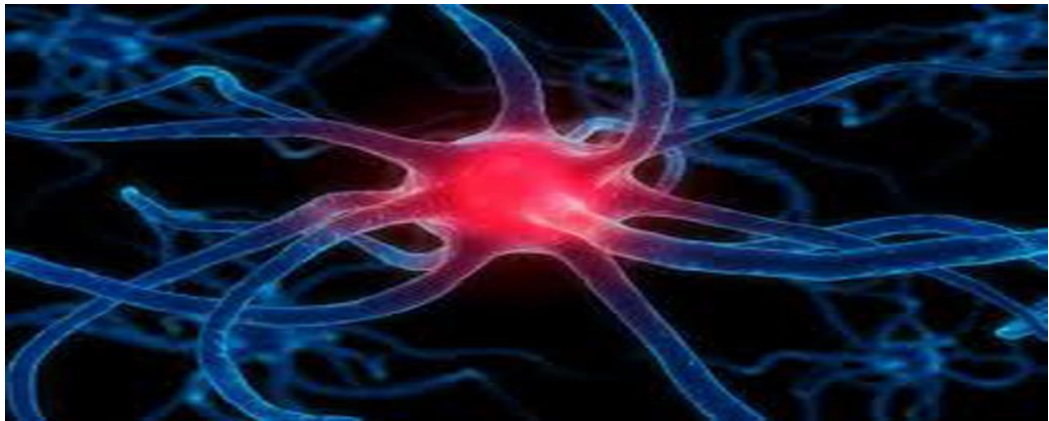

THANK YOU FOR YOUR ATTENTION